área oftalmológica avanzada
Dr. Vergés

UNIVERSITAT POLITÈCNICA DE CATALUNYA

Corrección de la Presbicia ¿Es ya una realidad?

Carlos Vergés
Jorge Cazal
Jesus Marín

área oftalmológica avanzada
Dr. Vergés

PRESBICIA = Déficit en visión cercana

- Afaquia - Pseudofaquia
- Insuficiencia de Acomodación
- Presbicia

área oftalmológica avanzada
Dr. Vergés

AFAQUIA - PSEUDOFAQUIA

- Lentes de contacto
- PiggyBack con LIO monofocal para monovisión
- PiggyBack con LIO multifocal
- Ablación corneal láser con perfil asférico o con perfil multifocal
- Inlay corneal: Lente o Anillo (Acufocus)

INSUFICIENCIA DE ACOMODACIÓN

Capacidad acomodativa inferior al nivel que corresponde a la edad del paciente

- ♦ Insuficiencia de convergencia
- ♦ Hipermetropia
- ♦ Radiación ultravioleta
- ♦ Inflamación ocular
- ♦ Fatiga y estrés
- ♦ Medicación sistémica
- ♦ Diabetes
- ♦ Patología Tiroidea
- ♦ Esclerosis multiple
- ♦ Distrofias musculares

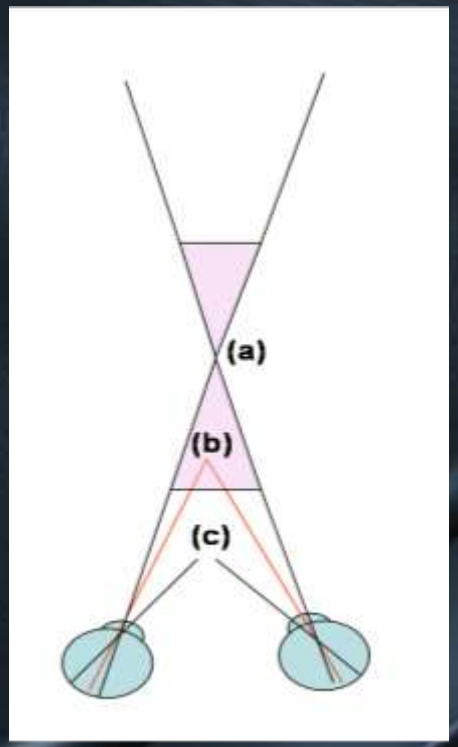

PRESBICIA

Condición refractriva debida a la edad, en la que se reduce la habilidad acomodativa de los ojos para enfocar los objetos cercanos.

Dictionary of Optometry and Visula Science 2009

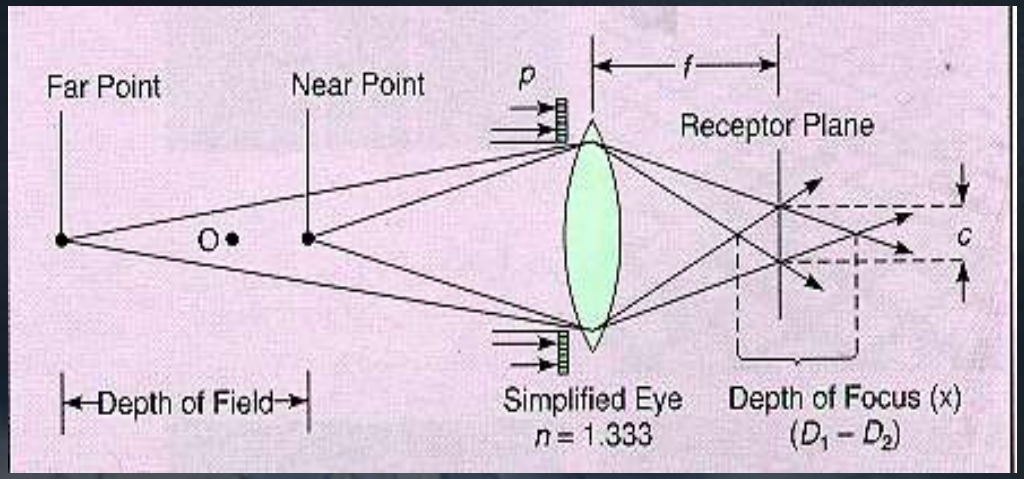

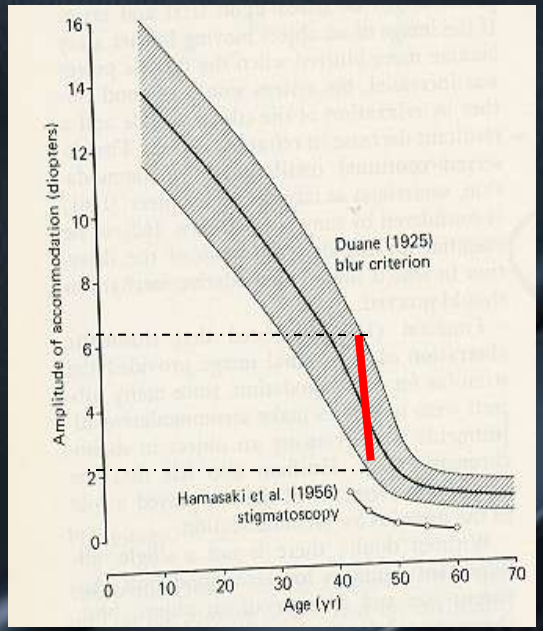

CRISTALINO PRÉSBITA

DESCENSO DE LA ACOMODACIÓN

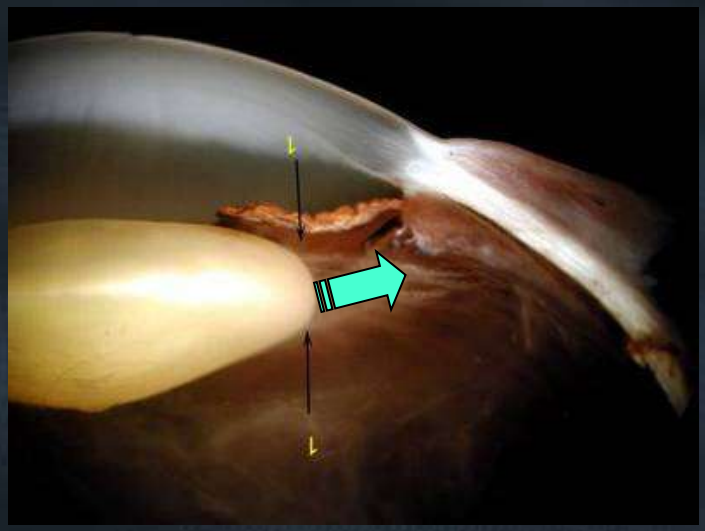

DESCENSO DE LA CALIDAD VISUAL

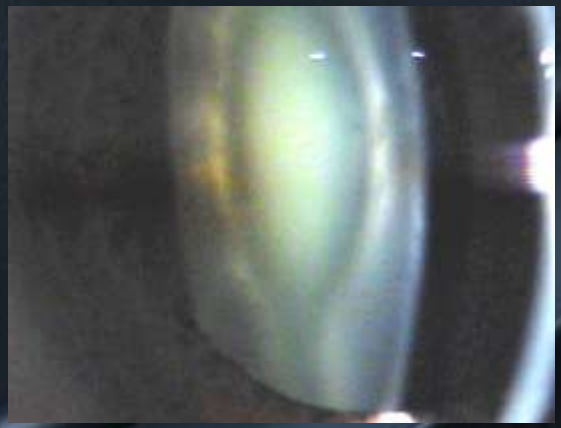

área oftalmológica avanzada
Dr. Vergés

CÓMO MEDIMOS LA ACOMODACIÓN

- Métodos subjetivos clásicos
- Métodos objetivos

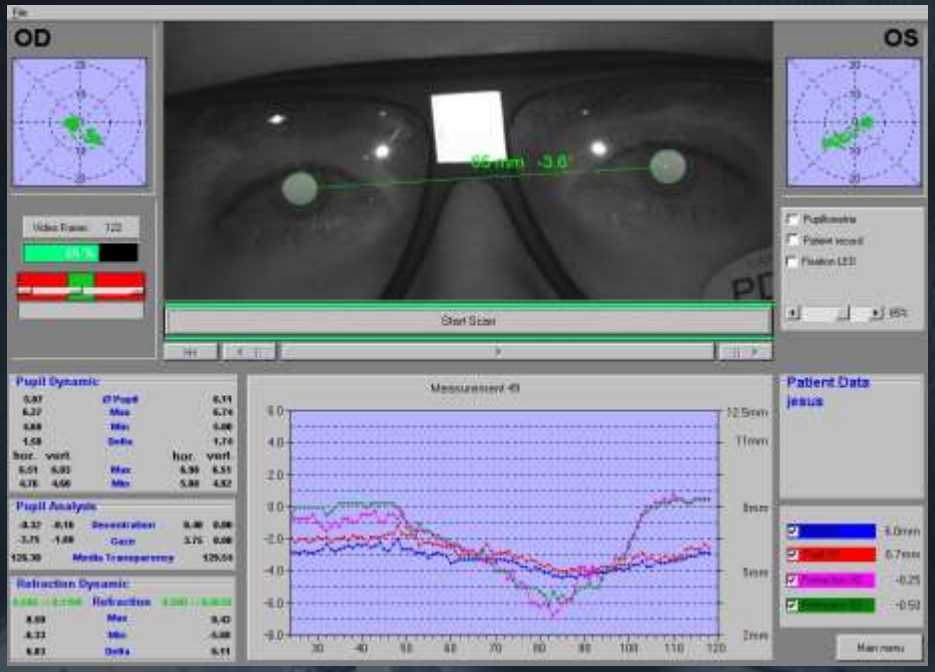

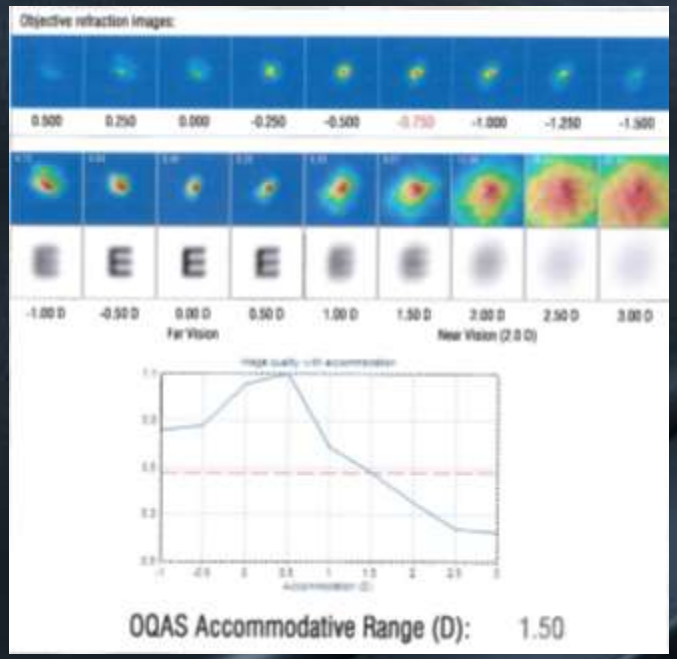

área oftalmológica avanzada
Dr. Vergés

ACOMODACIÓN DINÁMICA

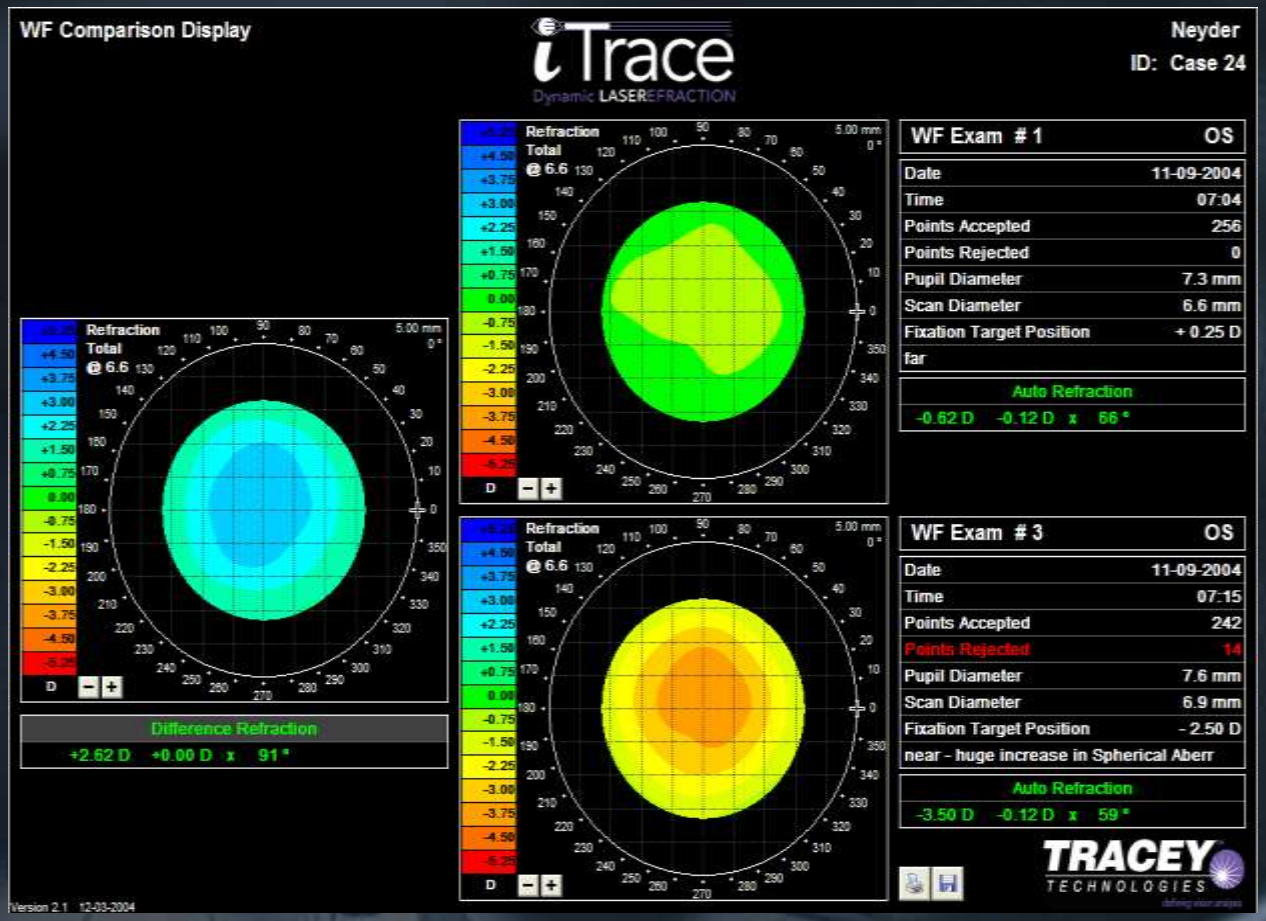

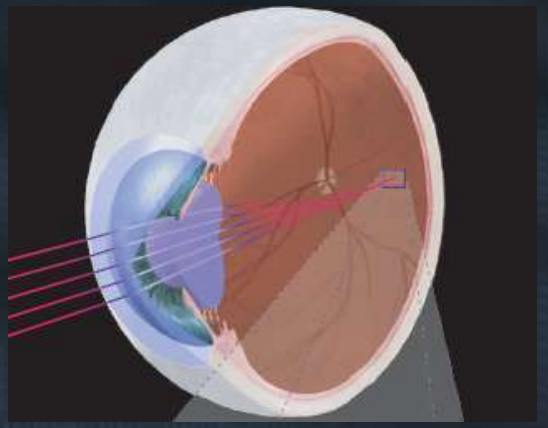



área oftalmológica avanzada
Dr. Vergés



OCT

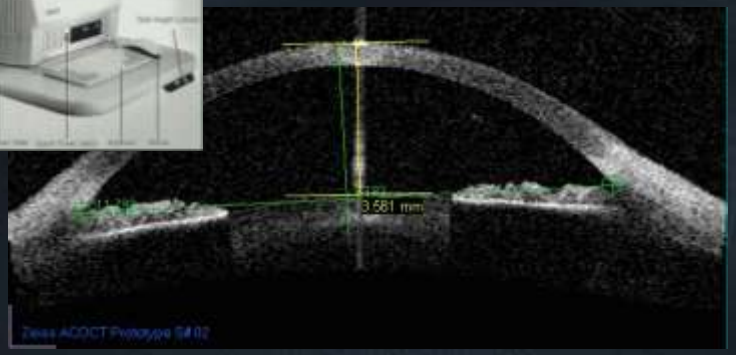



PENTACAM
Scheimpflug





VHF

CÓMO SE TRATA LA PRESBICIA

- **Gafas: Bifocales o Progresivas.**
- **Lentillas Multifocales**
- **Monovisión con Lentes Intraoculares**
- **Lentes Intraoculares Multifocales**
- **Lentes Intraoculares Pseud-oacomodativas**
- **Láser Corneal (Presbi-LASIK)**
- **Inlays Corneales (Acufocus)**
- **Bandas Esclerales (Baikoff o Refocus)**
- **Terapia Visual (Incremento de acomodación y mejora de la sensibilidad al contraste)**

TRATAMIENTO DE LA PRESBICIA

- **Incremento de volumen del cristalino**

REDUCCIÓN EN LA AMPLITUD DE ACOMODACIÓN

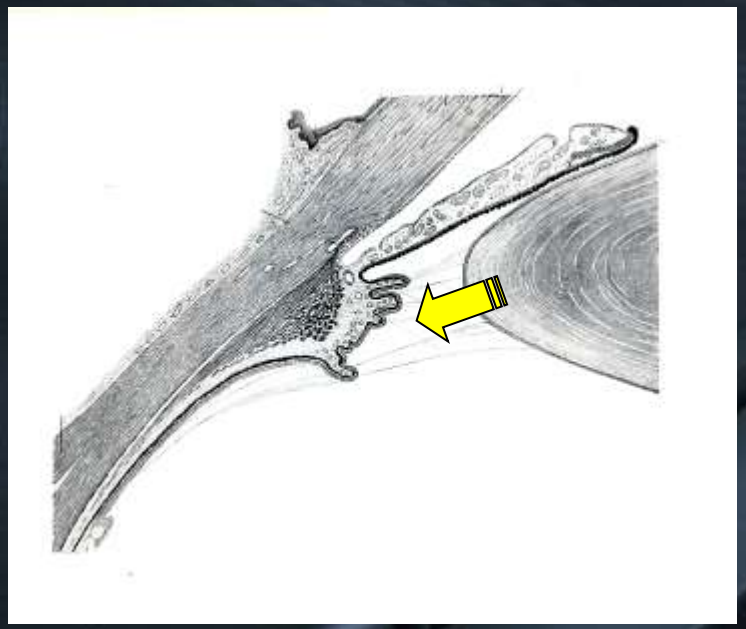

Expansión del "Anillo Ciliar"
Fukasako, Lim, Schachar ?

TRATAMIENTO DE LA PRESBICIA

- **Ciliary Sphincter (J Coleman, 1970)**



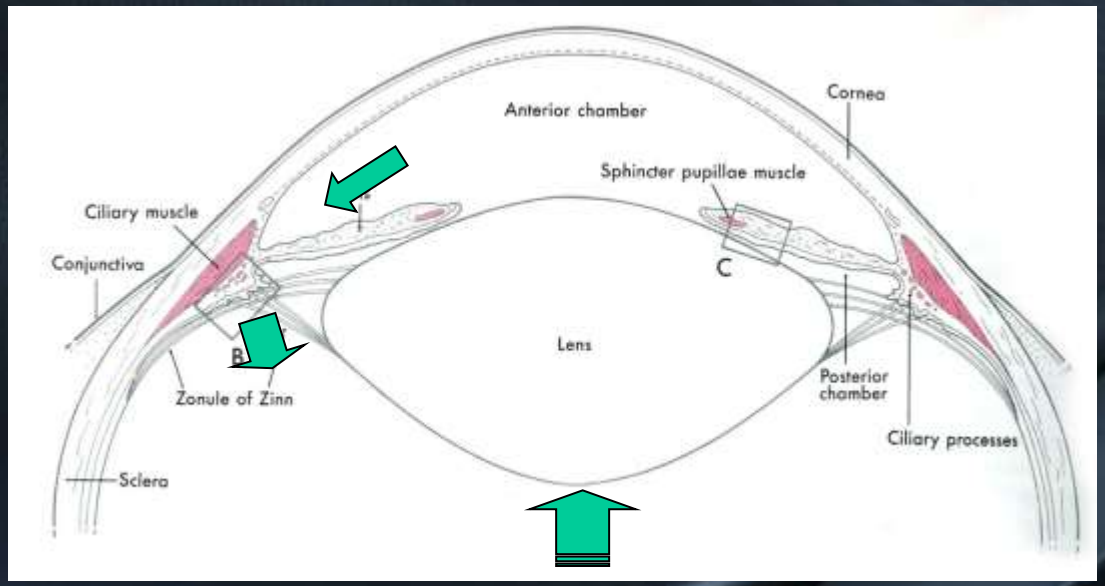

TRATAMIENTO DE LA PRESBICIA

- **Ciliary Sphincter (J Coleman, 1970)**

- LIOs *ACOMODATIVAS*

- *BAIKKOF CILIARY SUPRASEGMENTS*

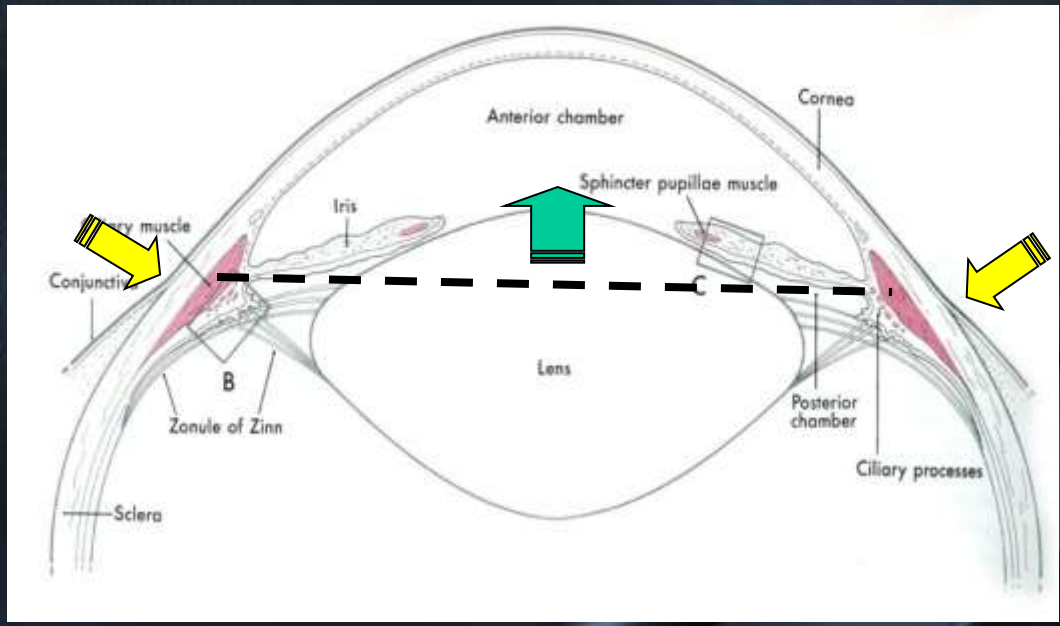

TRATAMIENTO DE LA PRESBICIA

- **Scattering de luz**
- **Cámbios en las aberraciones cromáticas**
- **Cámbios en las aberraciones esféricas**



Cámbios refractivos y descenso de la calidad visual

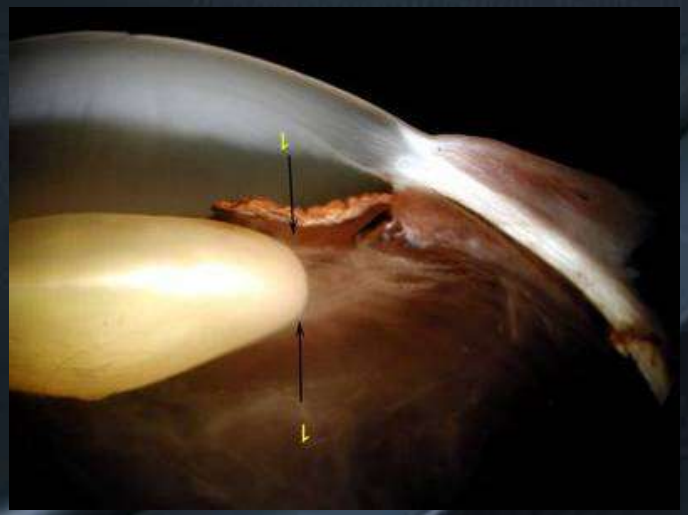

FACO-REFRACTIVA
Monovisión o Multifocales

área oftalmológica avanzada
Dr. Vergés

CIRUGÍA ESCLERAL EN EL TRATAMIENTO DE LA PRESBICIA

- **EXPANSIÓN ANILLO CILIAR**
  - **Cirugía Incisional (Fukasaco 1996, Bulacio (2002)**
  - **Laser Sculping (1999, Dementiev 2005)**
  - **Bandas Esclerales (Schachar 2003, REFOCUS 2006)**
- **CONTRACCIÓN ANILLO CILIAR**
  - **Bandas Esclerales de Baifoff (J. Coleman 1979)**

área oftalmológica avanzada
Dr. Vergés

FUKASAKO RADIAL INCISIONS

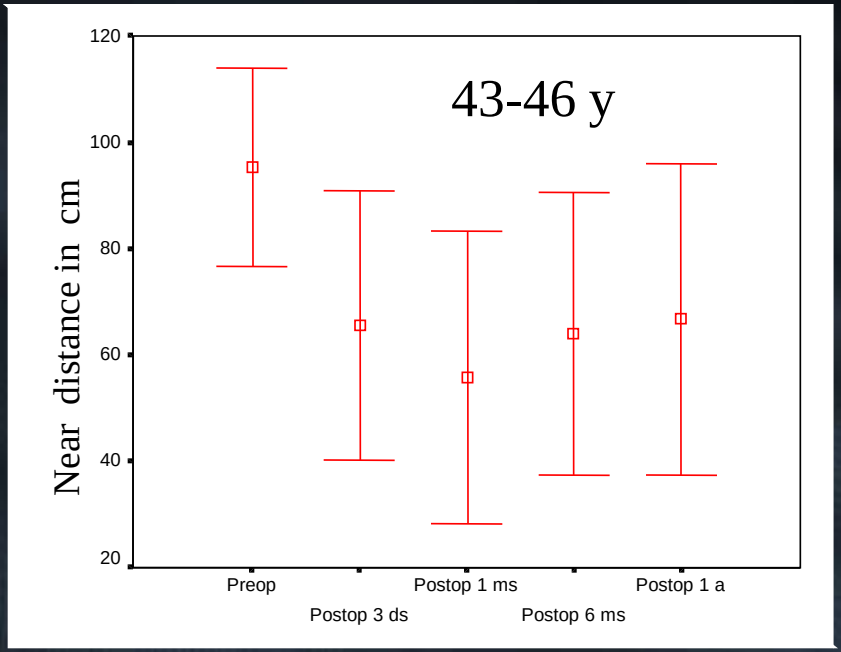

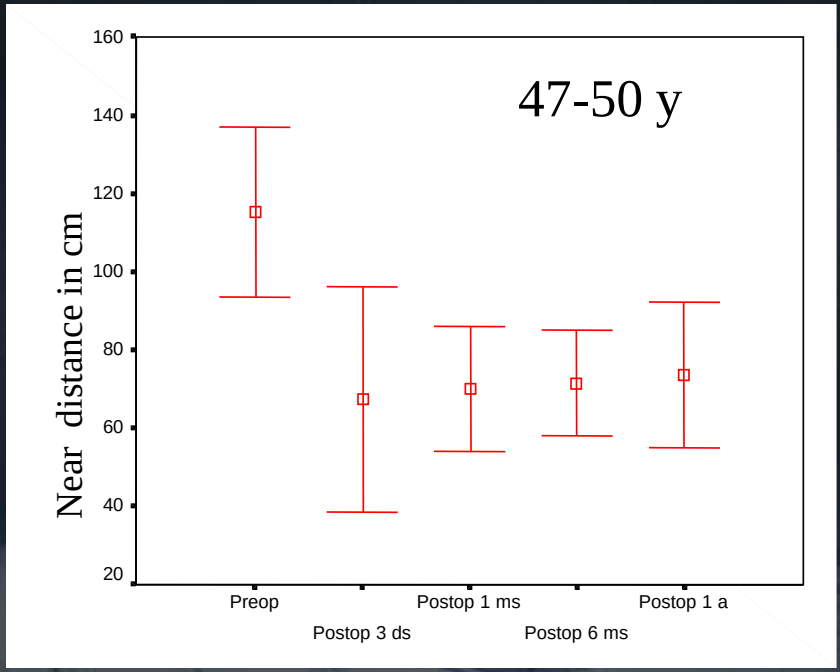

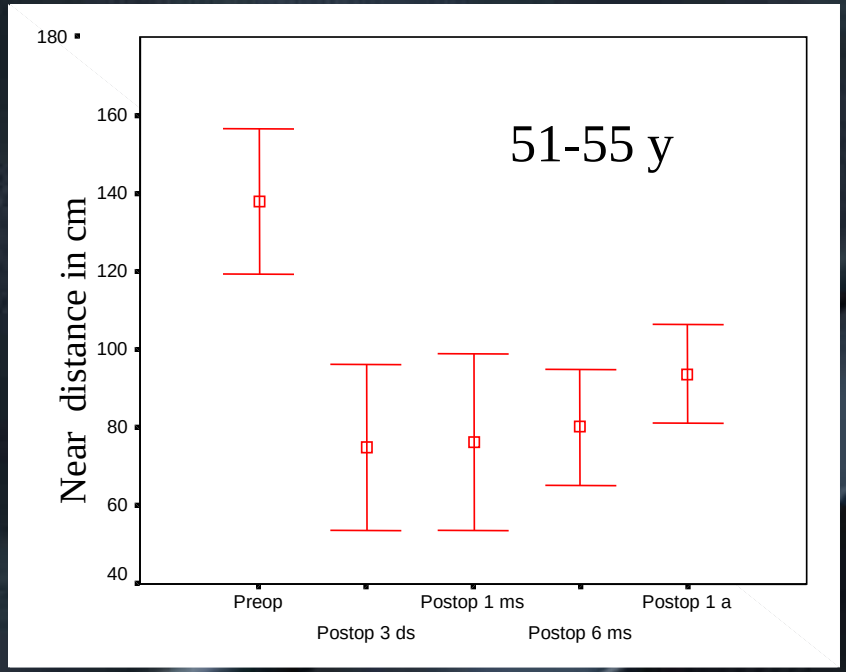

Er:YAG Laser. Handpiece for Presbiopya





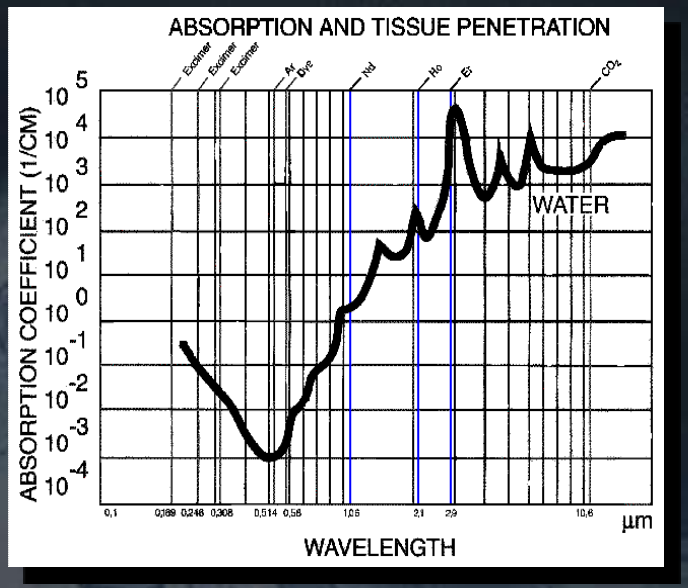

ASCLEPION-MEDITEC



LASER ASSISTED RADIAL SCLERECTOMY (LARS)

N : 12 eyes (6 p)
A : 45 – 55 y
8 F / 4 M
Emetropic (<0.5 D)
FU : 18 ms

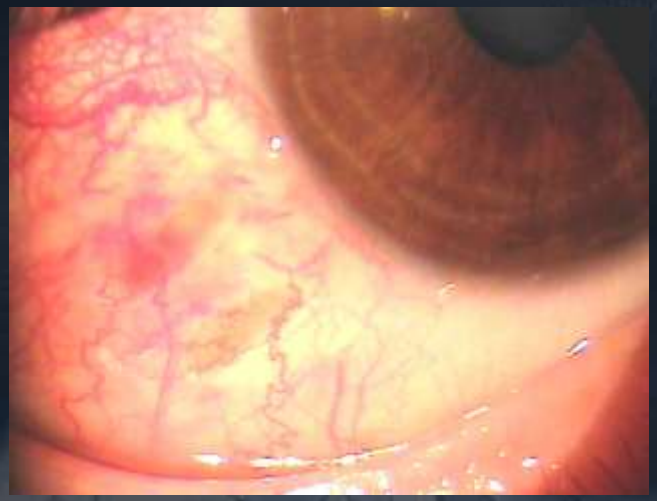

Δ Accommodation (D)

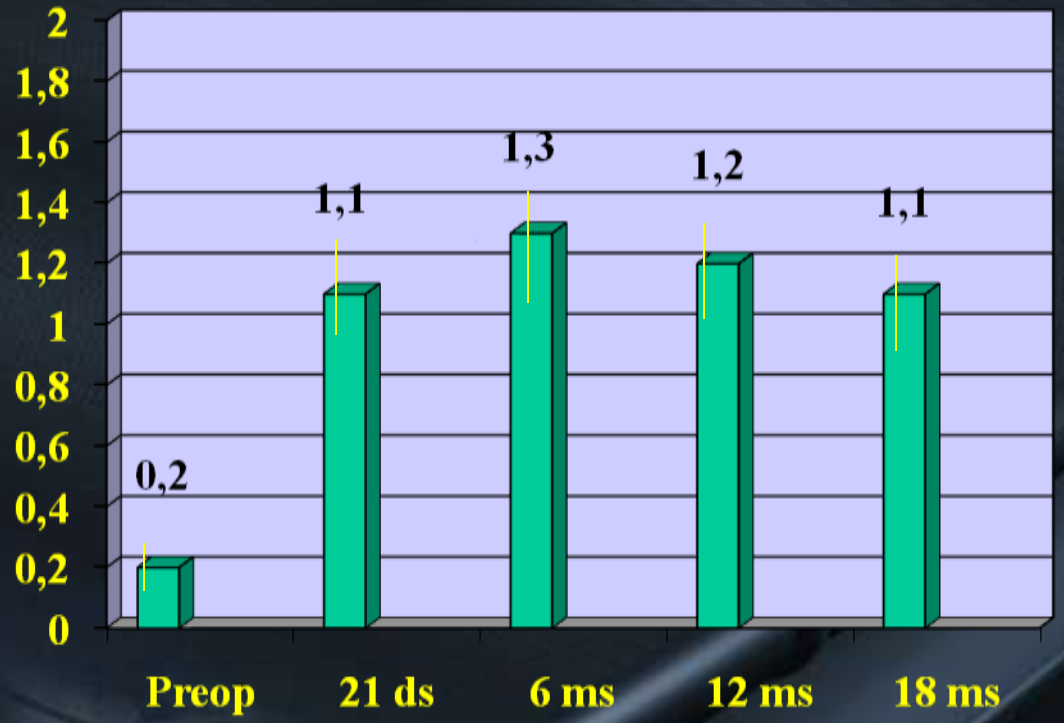

BAIKOFF CILIARY SUPRASEGMENTS

N : 16 eyes (8 p)
A : 45 – 55 y
8 F /8 M
Emetropic (<0.5 D)
FU : 18 ms

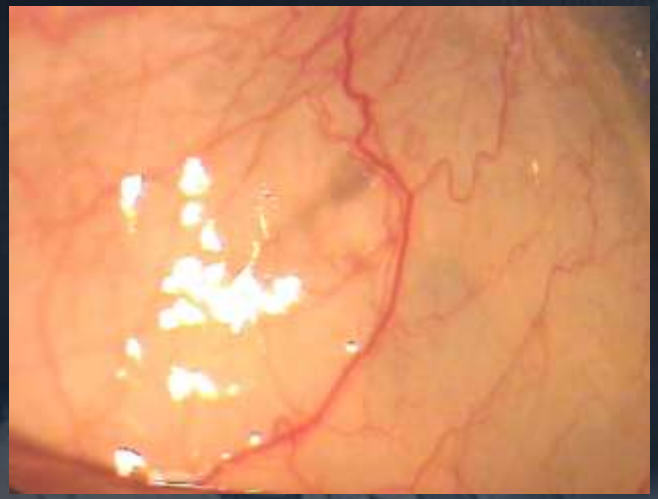

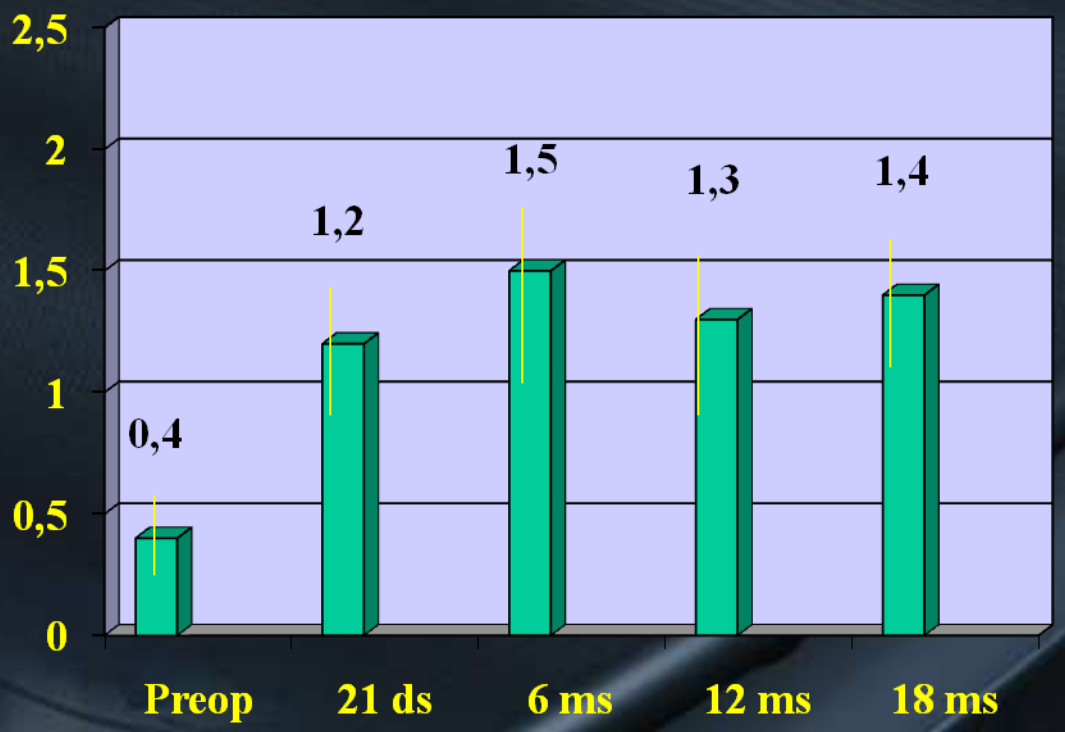

área oftalmológica avanzada
Dr. Vergés

Refocus Scleral Spacing Procedure





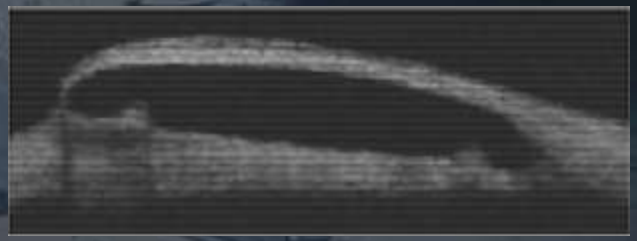



Cumulative Sloan VA in FDA IDE mean lines improved 2.4 ALL EYES

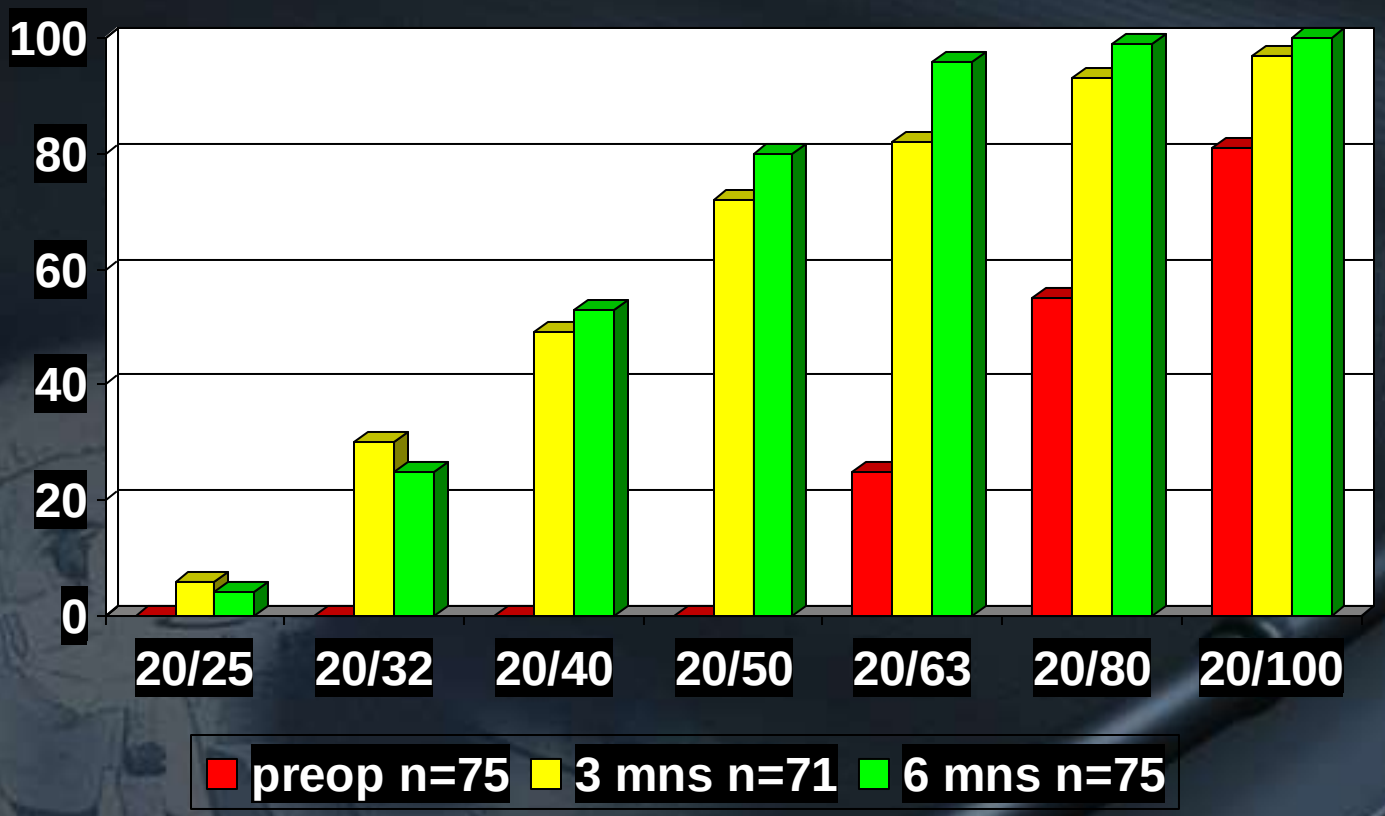

Correlating Accommodation and Improvement in Near Visual Acuity

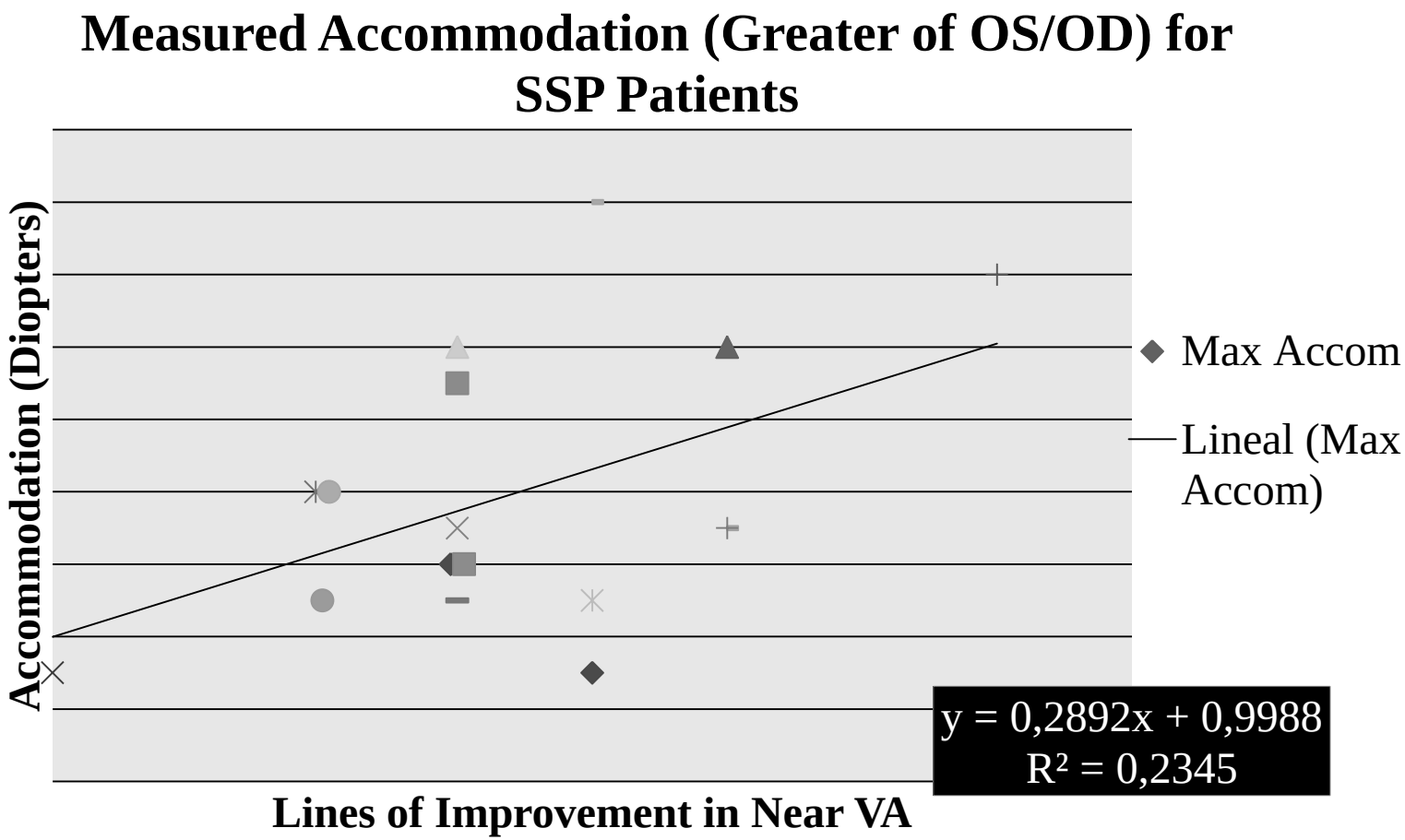

área oftalmológica avanzada
Dr. Vergés

ACOMODACIÓN DINÁMICA

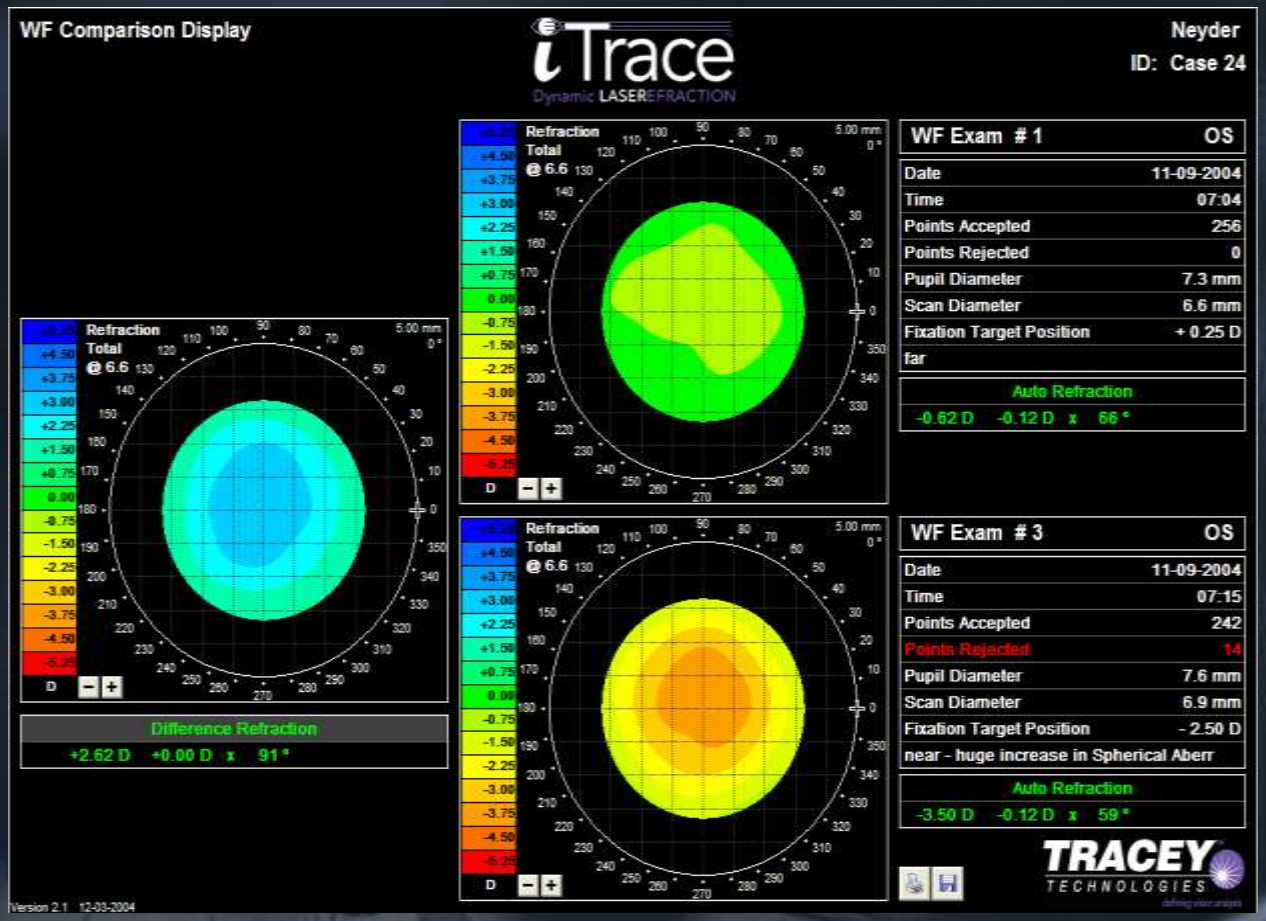

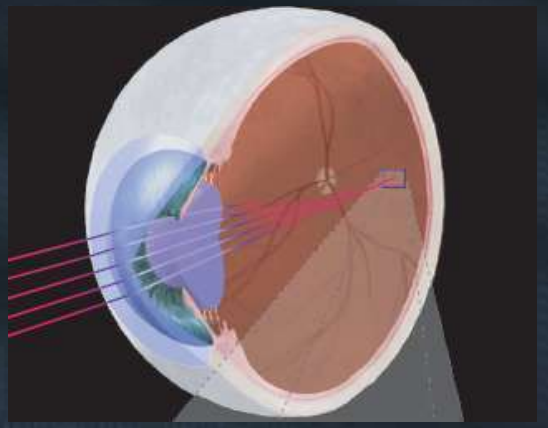



WF Comparison Display

iTrace by TRACEY TECHNOLOGIES

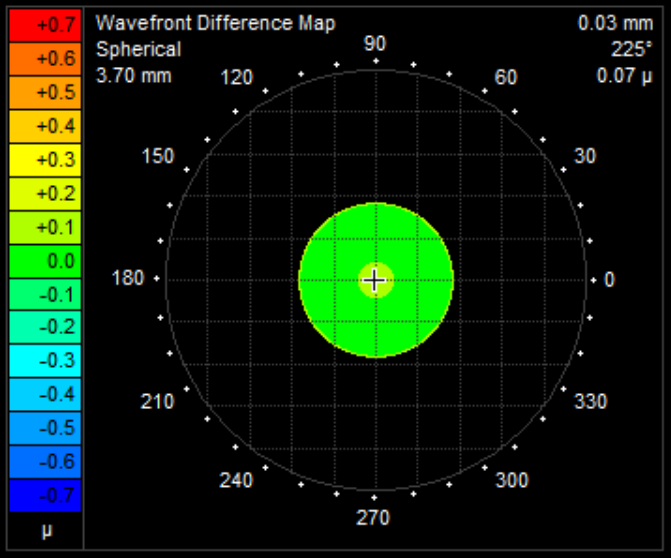

Auto Refraction

+0.37 D -0.25 D x 174°

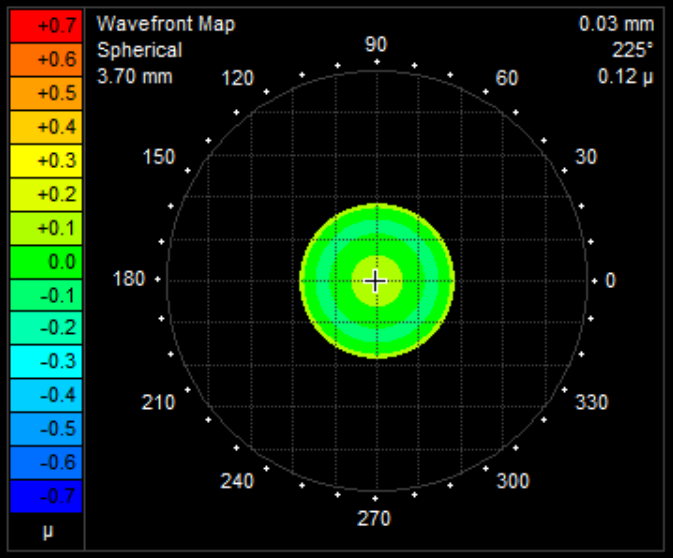

Date / Time	
Clinic	
Physician	
Operator	
Pupil / Scan Diameter	4.55 / 3.70 mm
Fixation Target Position	+ 0.75 D
Points Rejected	0
lejos	

Auto Refraction

-0.37 D -0.25 D x 161°

Notes

AV: 0.9

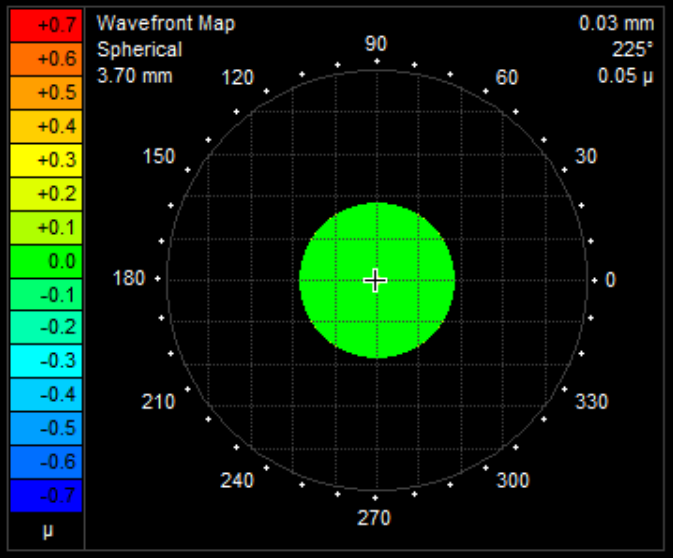

Date / Time	
Clinic	
Physician	
Operator	
Pupil / Scan Diameter	4.72 / 3.90 mm
Fixation Target Position	+ 0.25 D
Points Rejected	8
cerca 2	

Auto Refraction

-0.75 D -0.12 D x 124°

Notes

AV: J5

Version 4.0 2008-05-23

WF Comparison Display

iTrace by TRACEY TECHNOLOGIES

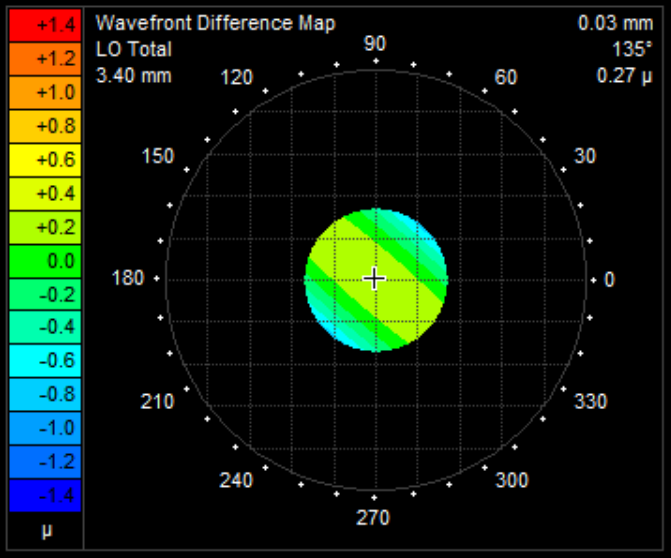

Auto Refraction

+0.75 D -0.75 D x 49°

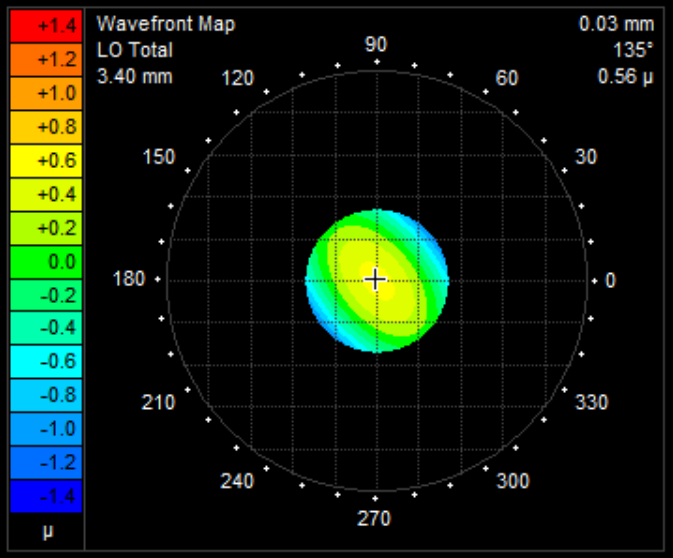

Date / Time
Clinic
Physician
Operator
Pupil / Scan Diameter 4.70 / 3.80 mm
Fixation Target Position + 2.25 D
Points Rejected 14
lejos

Auto Refraction

+1.12 D -0.75 D x 39°

Notes

AV: 0.9

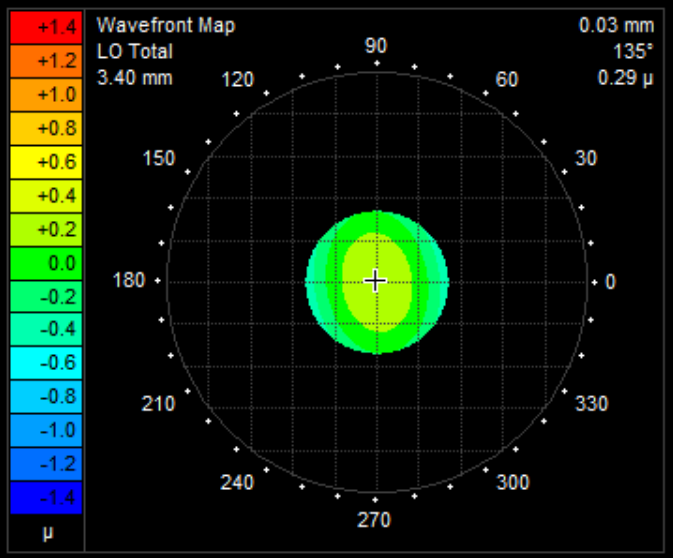

Date / Time
Clinic
Physician
Operator
Pupil / Scan Diameter --- / 3.40 mm
Fixation Target Position + 1.50 D
Points Rejected 8
cerca

Auto Refraction

+0.50 D -0.25 D x 8°

Notes

AV: J2

Version 4.0 2008-05-23

WF Comparison Display

iTrace by TRACEY TECHNOLOGIES

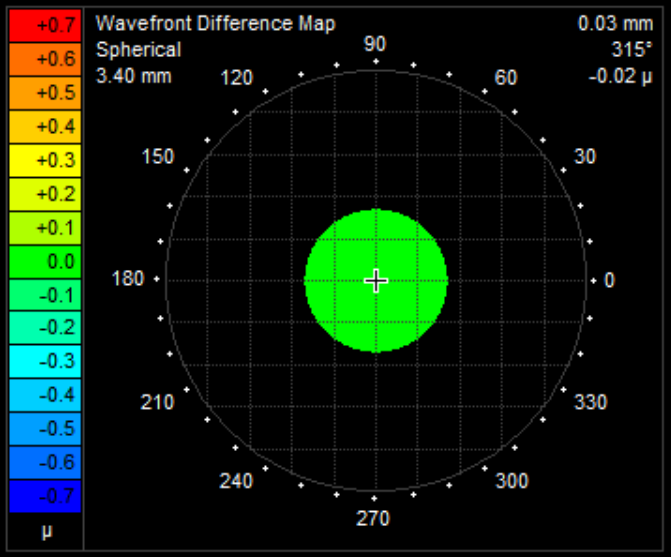

Auto Refraction

+0.75 D -0.75 D x 49°

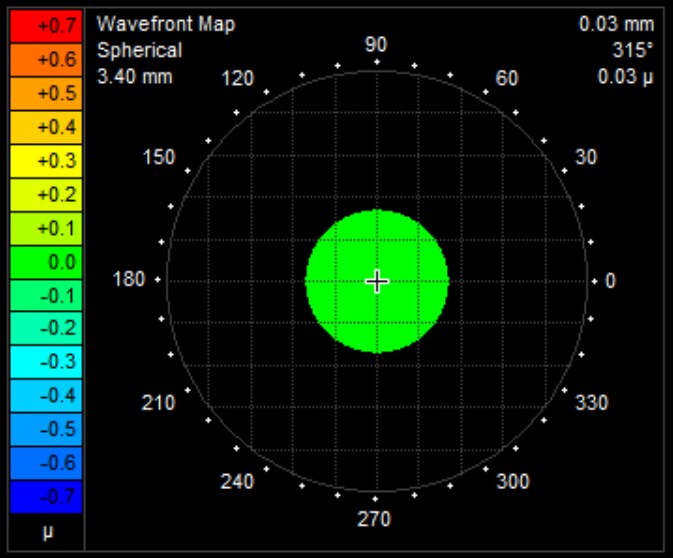

Date / Time
Clinic
Physician
Operator
Pupil / Scan Diameter 4.70 / 3.80 mm
Fixation Target Position + 2.25 D
Points Rejected 14
lejos

Auto Refraction

+1.12 D -0.75 D x 39°

Notes

AV: 0.9

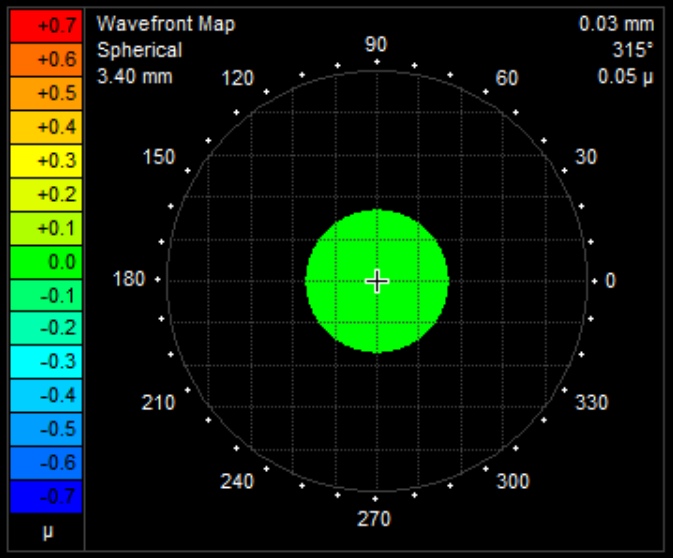

Date / Time
Clinic
Physician
Operator
Pupil / Scan Diameter --- / 3.40 mm
Fixation Target Position + 1.50 D
Points Rejected 8
cerca

Auto Refraction

+0.50 D -0.25 D x 8°

Notes

AV: J2

Version 4.0 2008-05-23

WF and CT Summary Display

iTrace by TRACEY TECHNOLOGIES

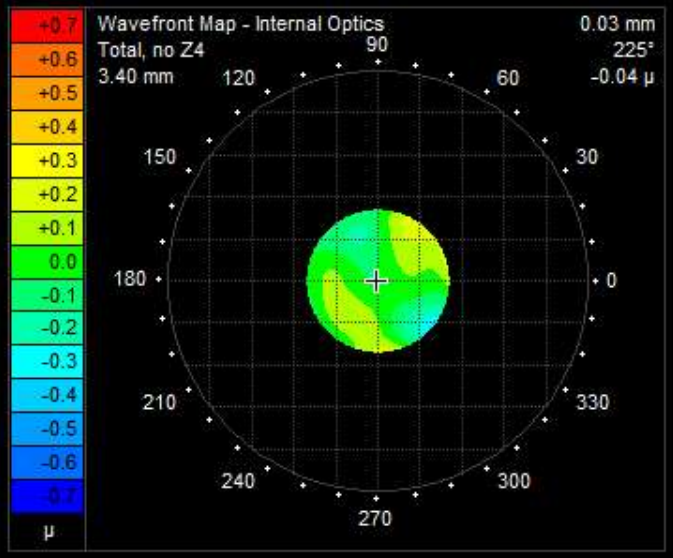

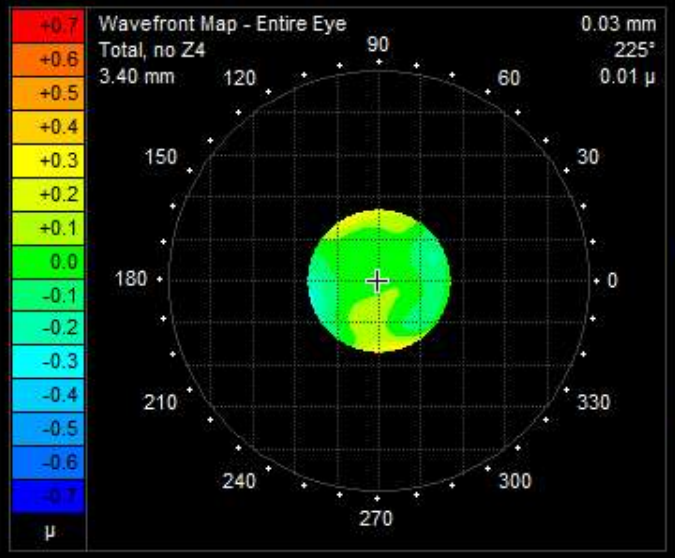

Date / Time	
Clinic	
Physician	
Operator	
Pupil / Scan Diameter	--- / 3.40 mm
Fixation Target Position	+ 1.50 D
Points Rejected	8
cerca	

Auto Refraction

+0.50 D -0.25 D x 8°

RMS @ D = 3.40 mm

Total	0.190 µ
LO Total	0.182 µ
HO Total	0.052 µ

Notes

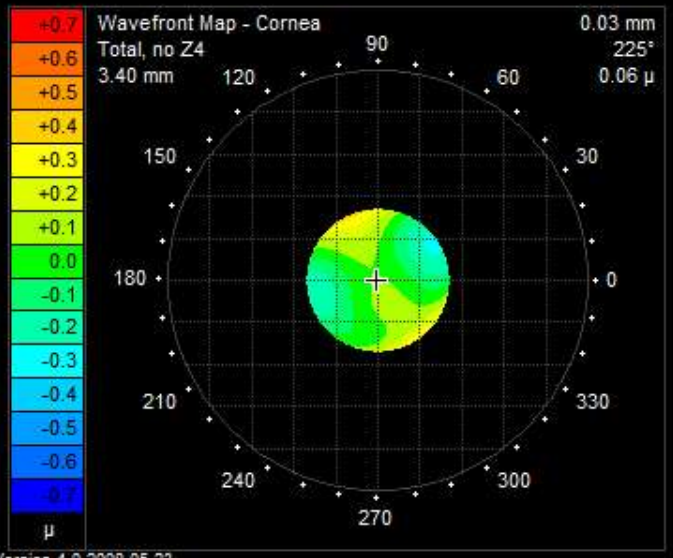



Date / Time	
Clinic	
Physician	
Operator	

Sim K

Steep	8.26 mm	/ 40.86 D	@	119°
Flat	8.33 mm	/ 40.54 D	@	29°
Delta		0.32 D	@	119°
Average	8.29 mm	/ 40.70 D		

Best Fit Conicoid @ D = 7.00 mm

R0 = 8.39 mm, Q = 0.60, e = 0.61

Central Power	40.70 D

I-S Axial Power @ D = 6.00 mm

Notes

Version 4.0 2008-05-23

¿Cirugía Escleral?: Sí o No

Hay evidencias que indican un posible mecanismo de acción para conseguir un efecto acomodativo significativo.

PRESBYOPIA TREATMENT

- **Corneal approach**

  Multifocal excimer ablation procedures
  Corneal Inlays
  Conductive keratoplasty (CK)



Retinal Spot Size

Type		spot ø distant	spot ø near	spectacle correction
Q-optimized cornea	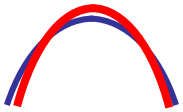	1.8	37.8 (**1.2**)	**yes**
CSI		22.9 (21.9)	8.8 (8.2)	no
DSI		30.9	39.9 (37.9)	no
CSA		65.0 (62.8)	38.8 (14.7)	no

emmetrope, good Q	1.4
myopia -0.5	20.3
myopia -1.0	41.1

ALLEGRETTO Ajustando la asfericidad



Examination Data *A-CAT*

WaveLight®

Llobell Marias, Ester; 02-07-1969

Pupil

Diameter : 5.50 mm A-CAT : 6.73 mm

Pachymetry

Central thickness : 494 µm Applied drugs :

Pachymeter :

Clinical Refraction

Sph : -6.00 D Cyl : -0.50 D Axis : 0 ° VD : 12.0 mm

Keratometry

K1 : 42.00 D @ : 1 ° ε1 : 0.06 Q1: -0.00

K2 : 43.00 D @ : 91 ° ε2 : 0.00 Q2:

0.06
0.05
0.04
0.03
0.02
0.01
0.00

Surgeon Notes

n : Dr. Verges

ack Next

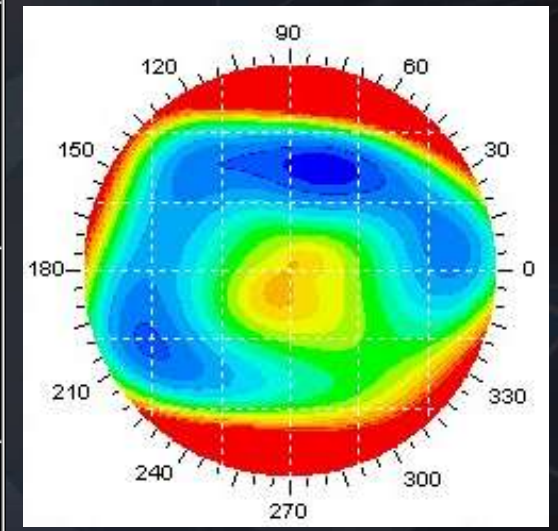

Dr. Carlos Verges

Ajustando la asfericidad

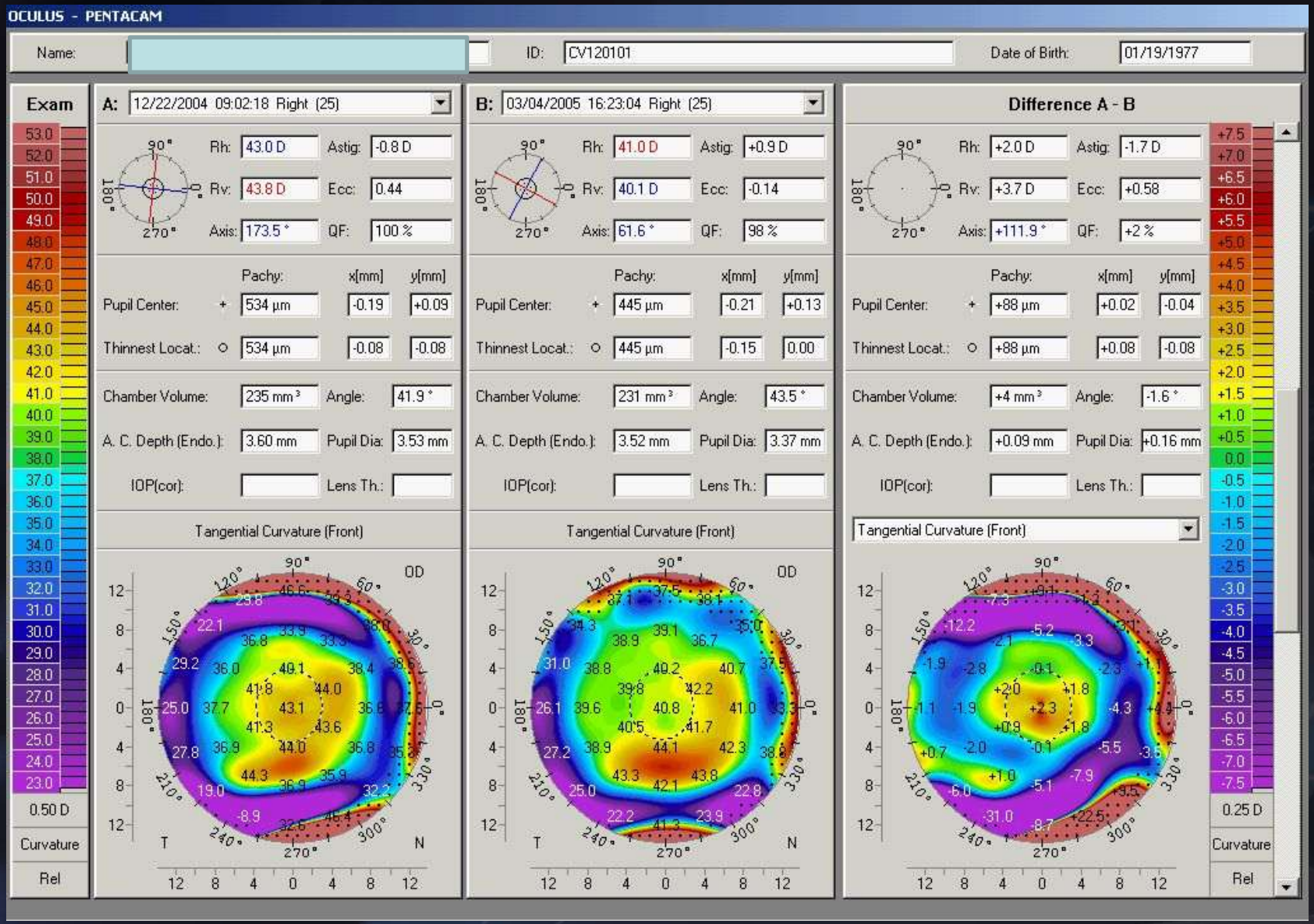

Monocular Simultaneous Uncorrected Distance and Near Vision (Allegretto 400 Q)

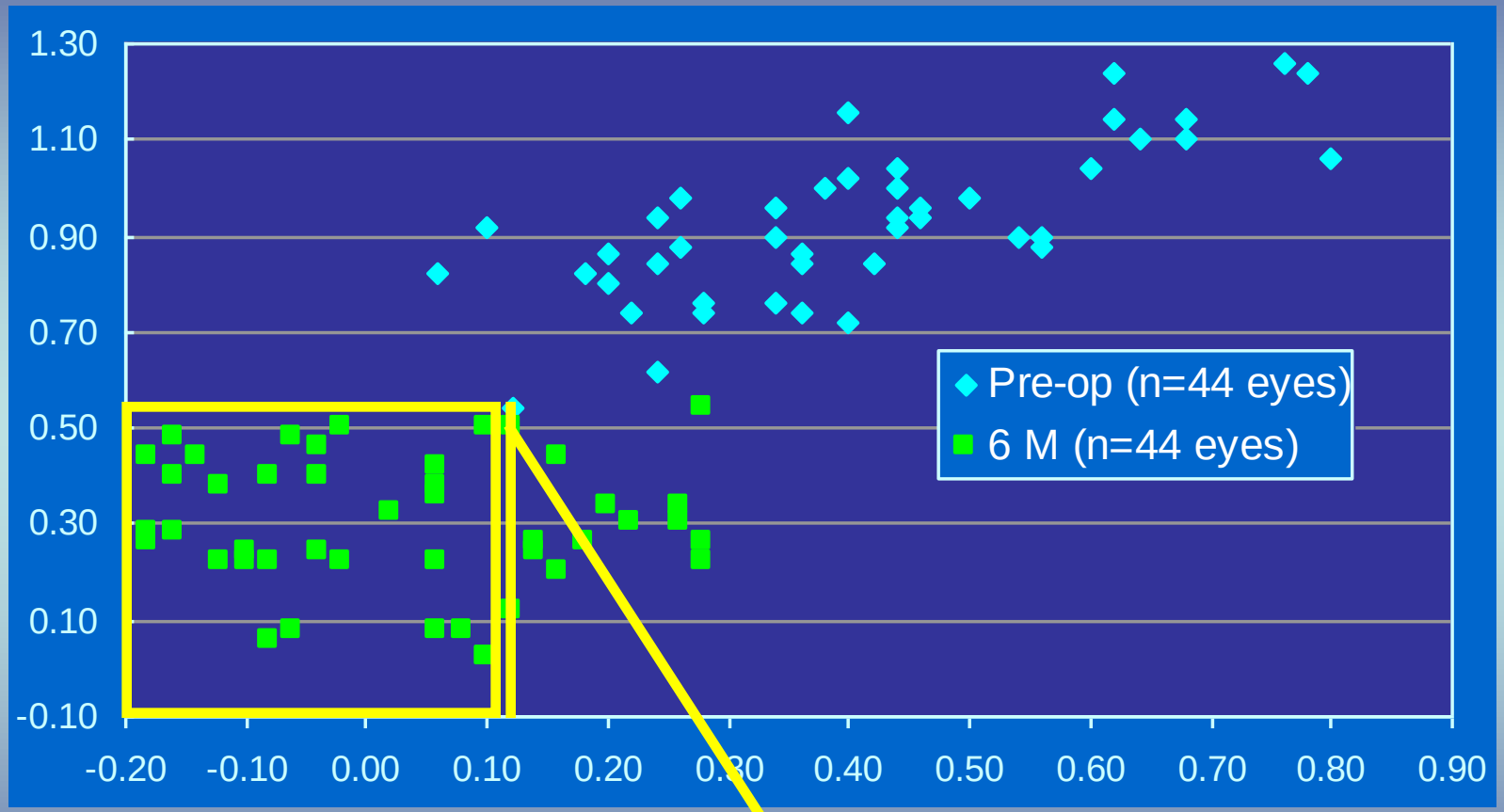

J3 or better

20/25 or better

77% of **eyes** achieve both 20/25 distance and J3 near **or better**

Questionnaire Results (Allegretto 400 Q)

Spectacle Use

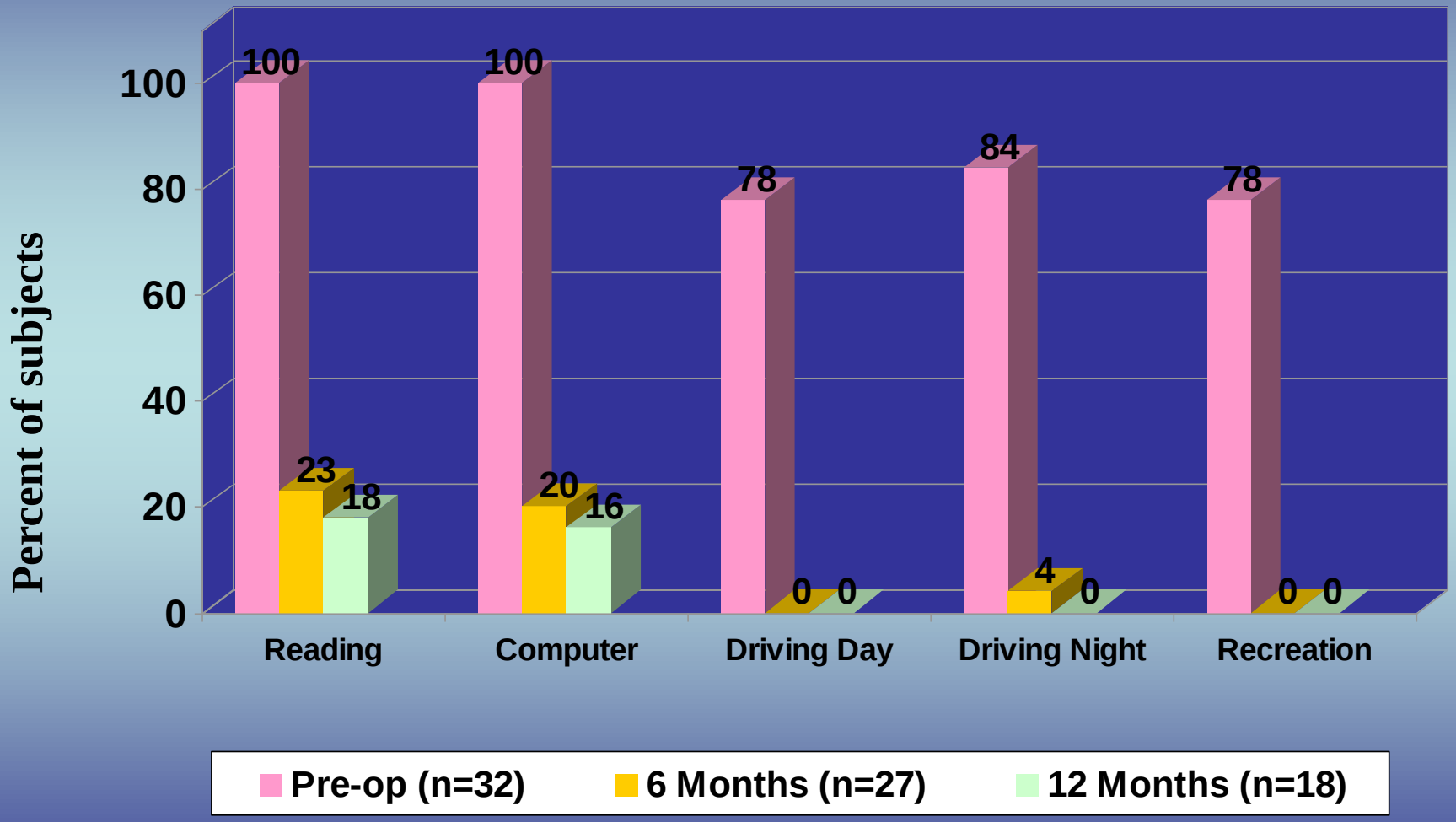

AcuFocus™ ACI 7000

How it Works

- The small aperture created by the AcuFocus™ ACI 7000 blocks the unfocused light on the retina



Blocks unfocused light

Allows focused light into the eye



The AcuFocus™ ACI 7000

Procedure

- Topical anesthetic eye drops
- Flap created
- The AcuFocus™ ACI 7000 is inserted and centered
- The flap is closed
- Taking less than 30 minutes - start to finish


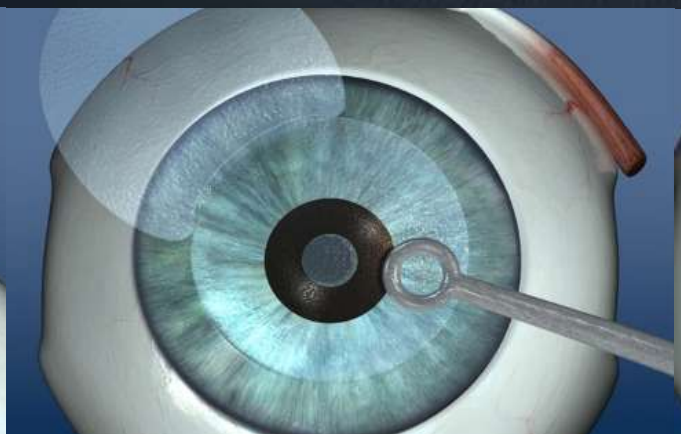
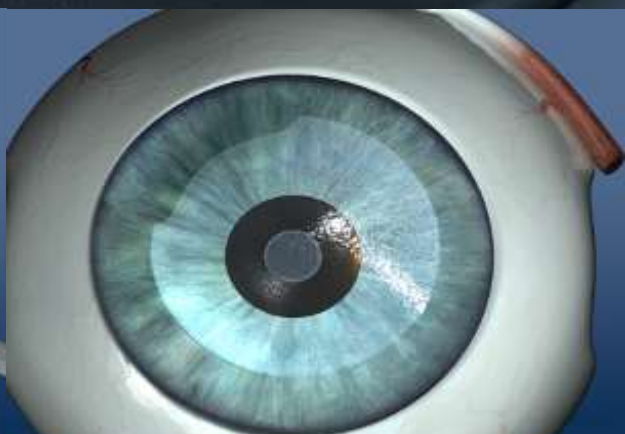

SLIT LAMP

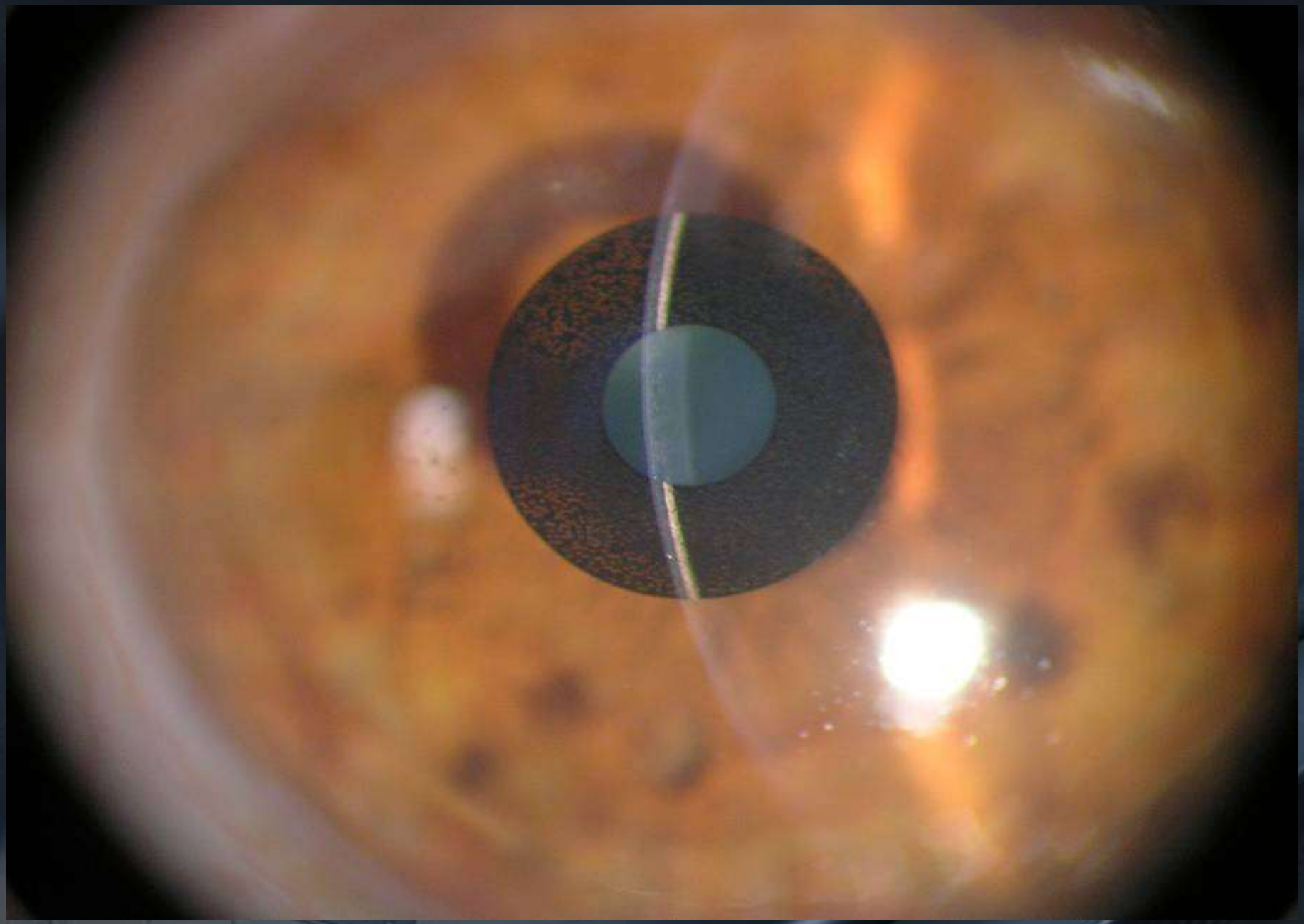

SLIT LAMP- Pharmacologically Dilated Pupil



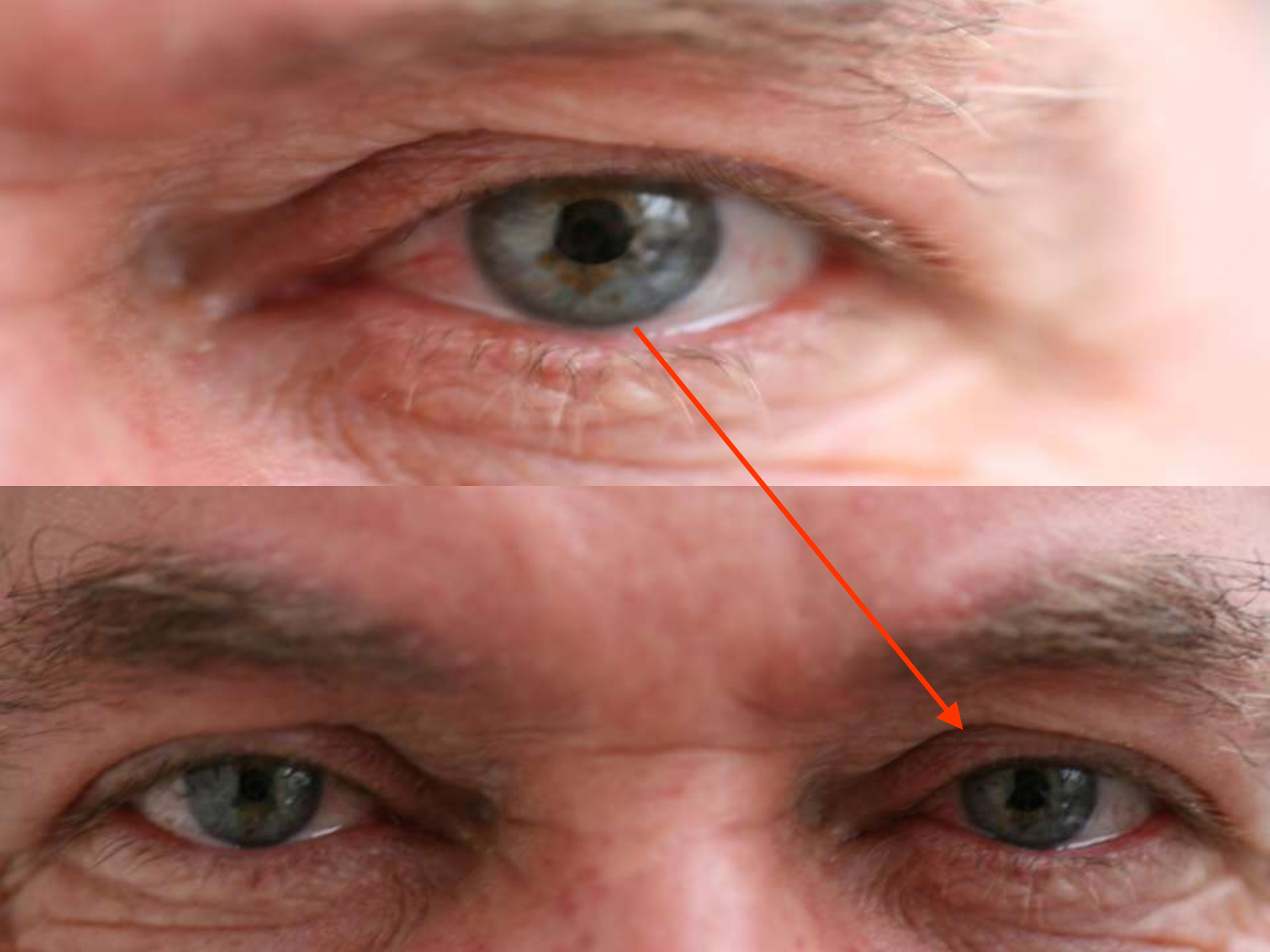

Depth of Focus

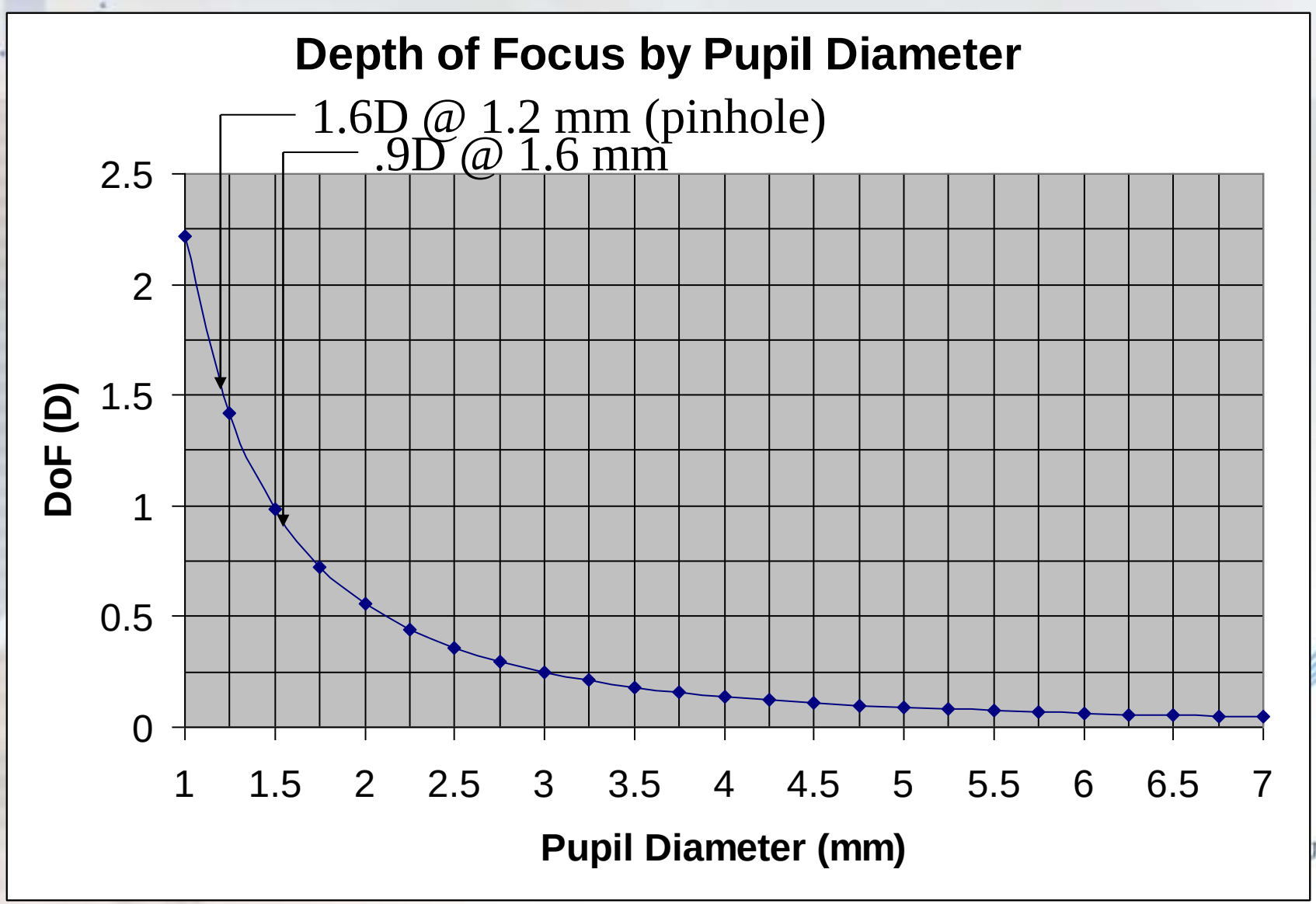

Potential Acuity

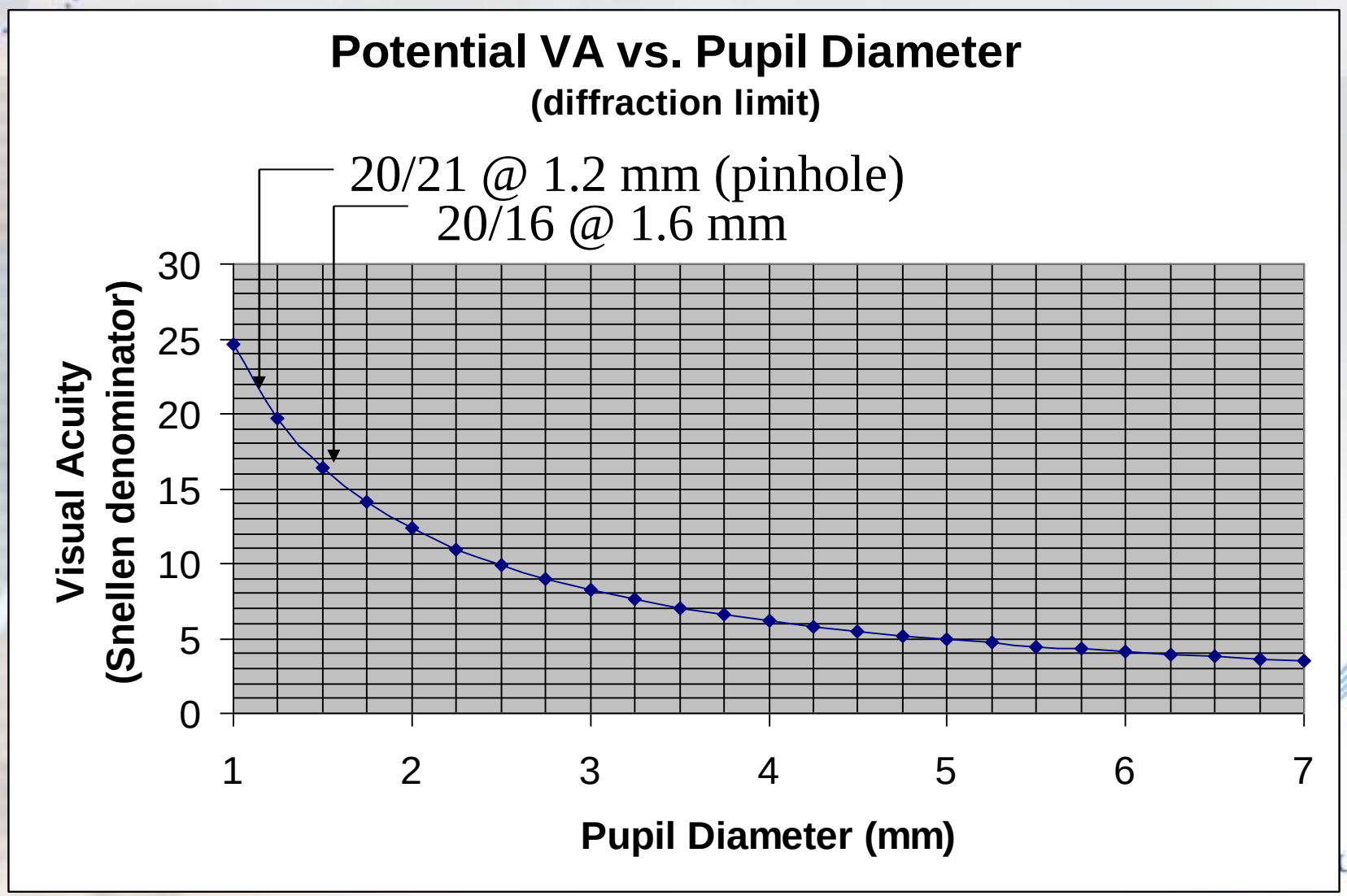

PRESBYOPIA TREATMENT

- **Intraocular Lens:**

Pseudo-accommodative IOLs



Multifocal IOLs



IOL POSITION

Size of the image

Tilting and descentration

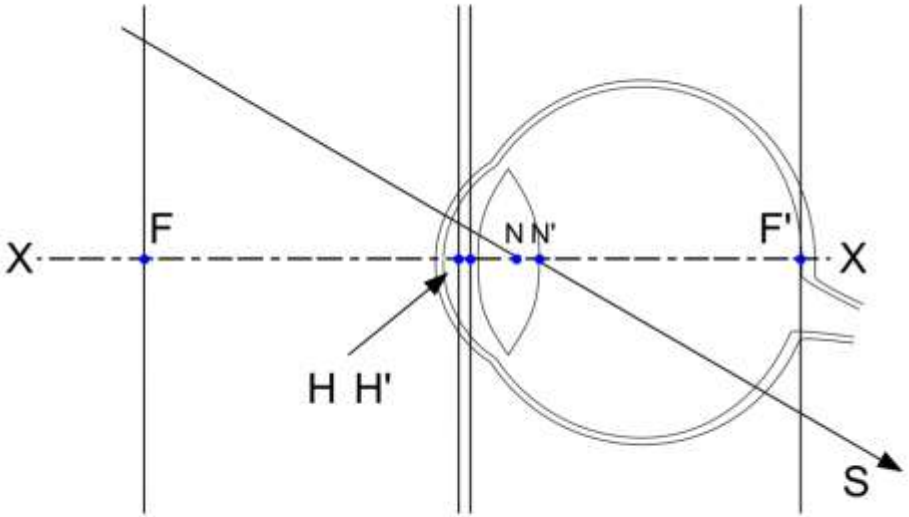

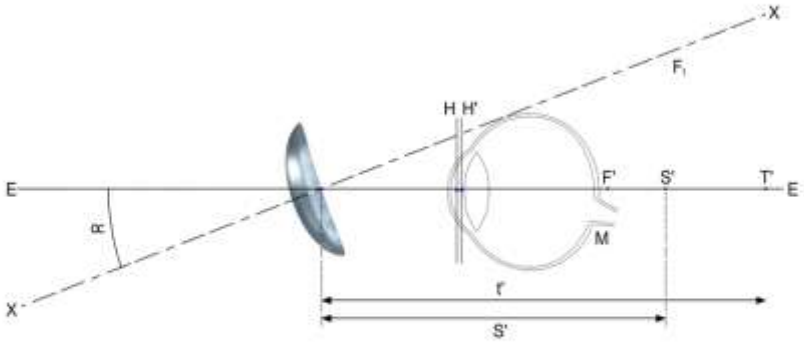

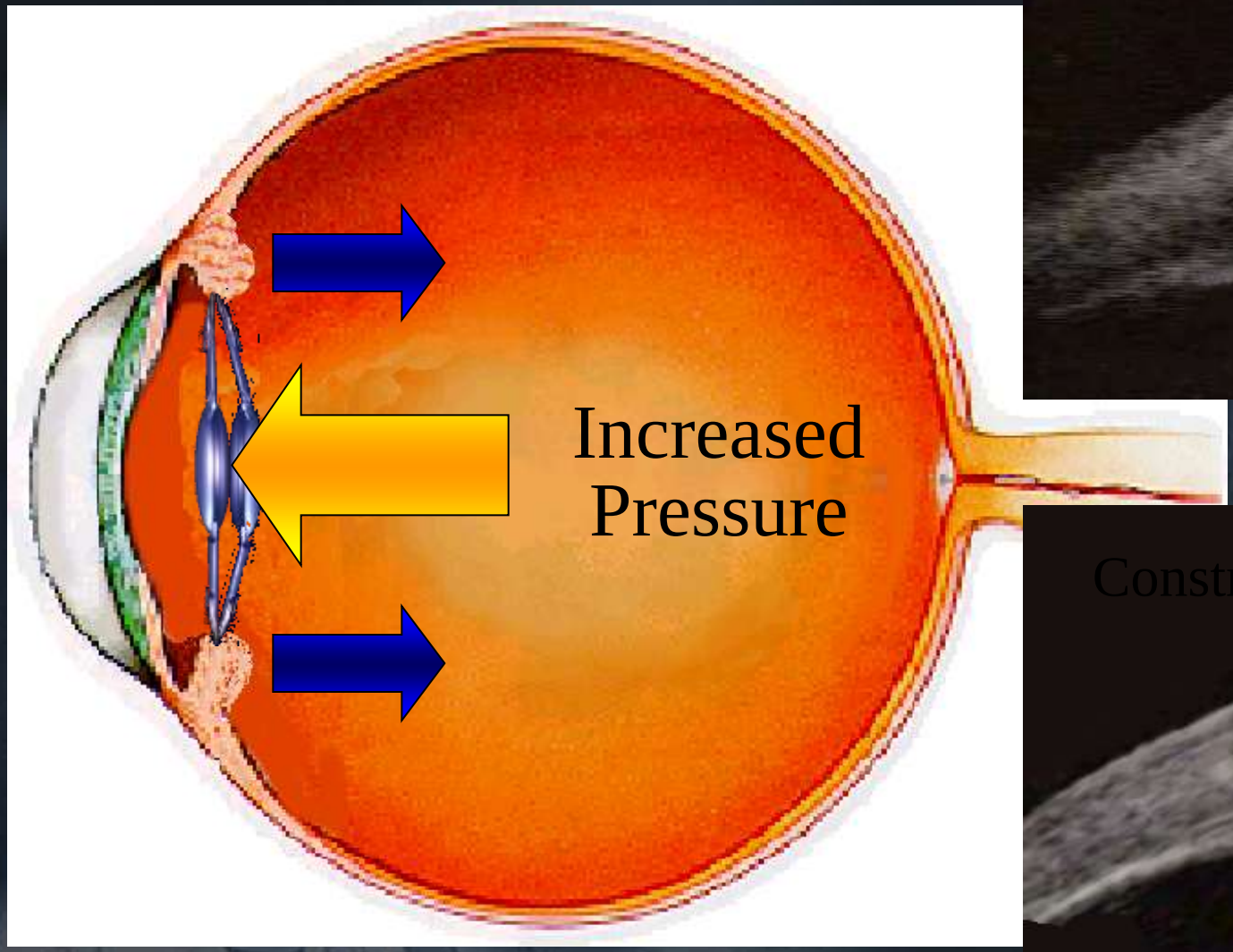
Increased
Pressure


Relaxed


Constricted

VISIOGEN SYNCHRONY

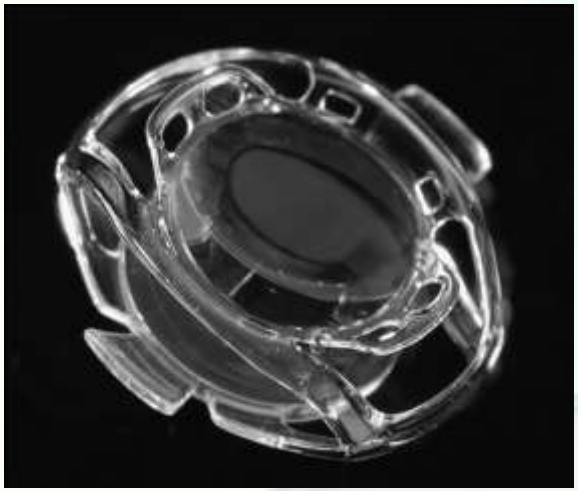

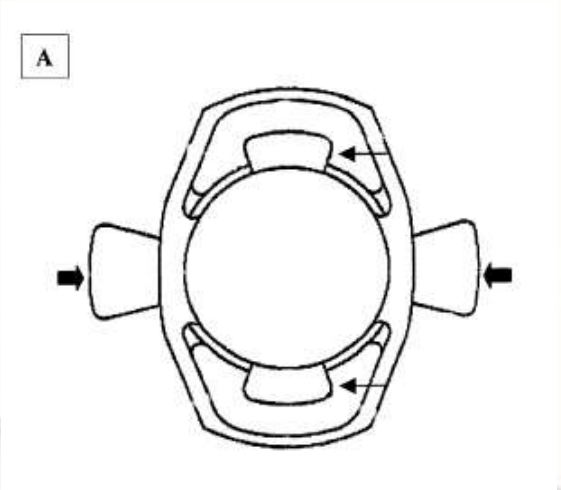

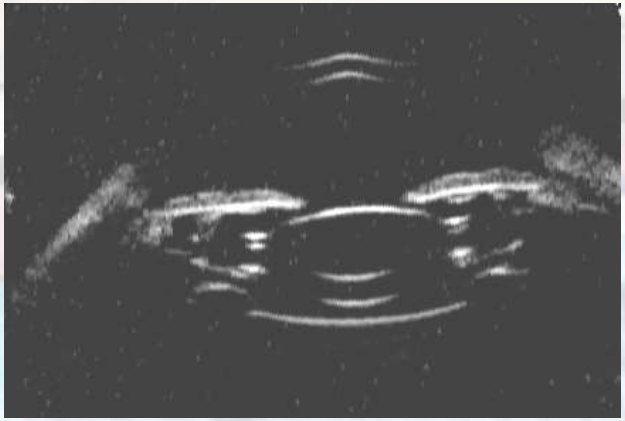

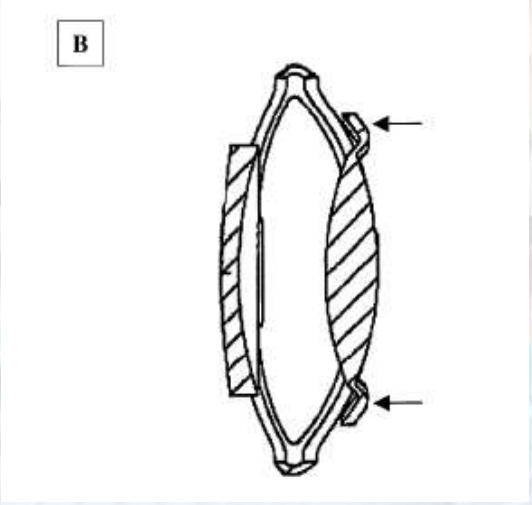

CRYSTALENS

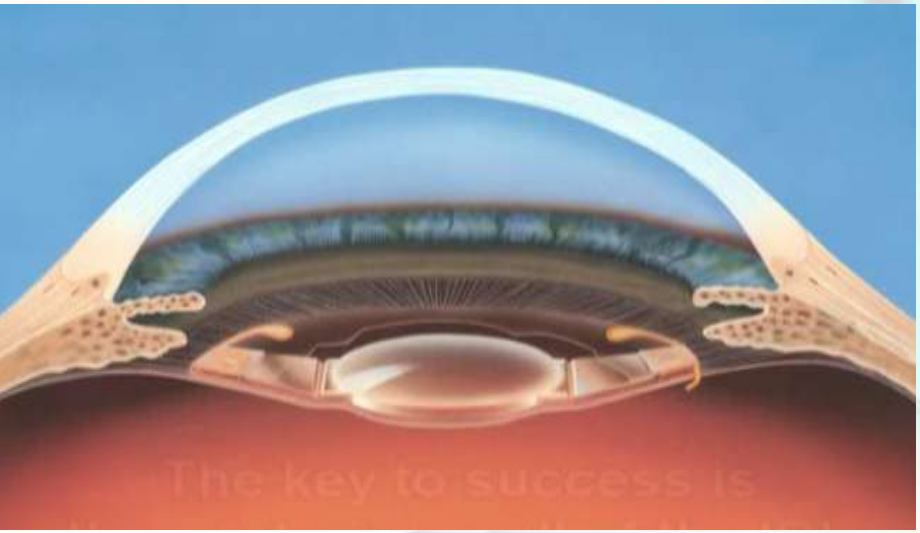

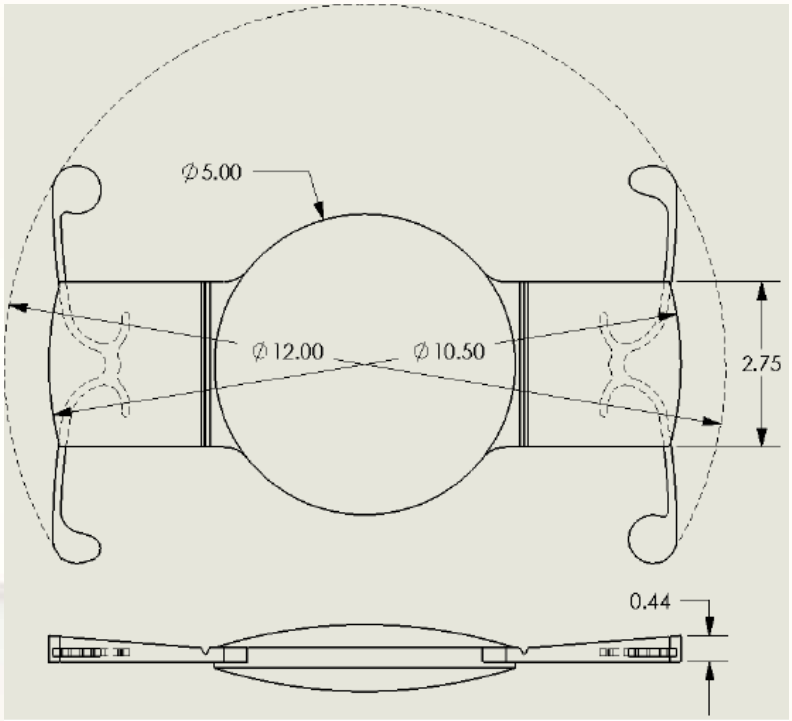

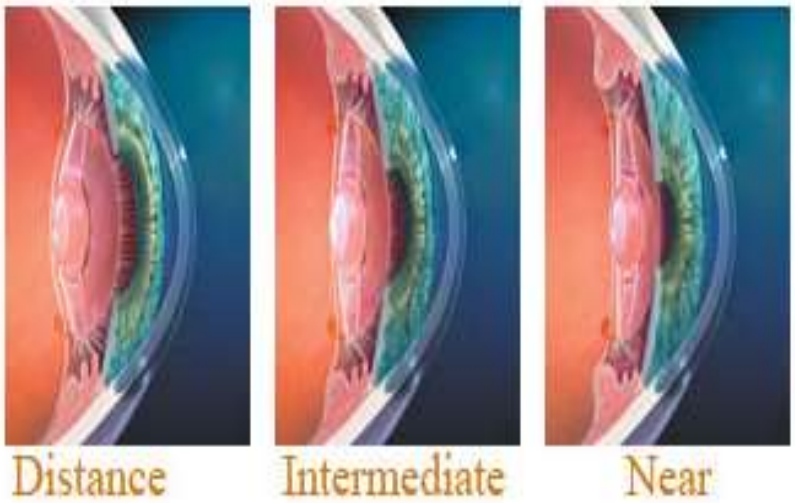





Synchrony dual-optic accommodating intraocular lens Part 1: Optical and biomechanical principles and design considerations

Stephen D. McLeod, MD, Luis G. Vargas, MD, Val Portney, PhD, Albert Ting, PhD

J CATARACT REFRACT SURG - VOL 33, JANUARY 2007

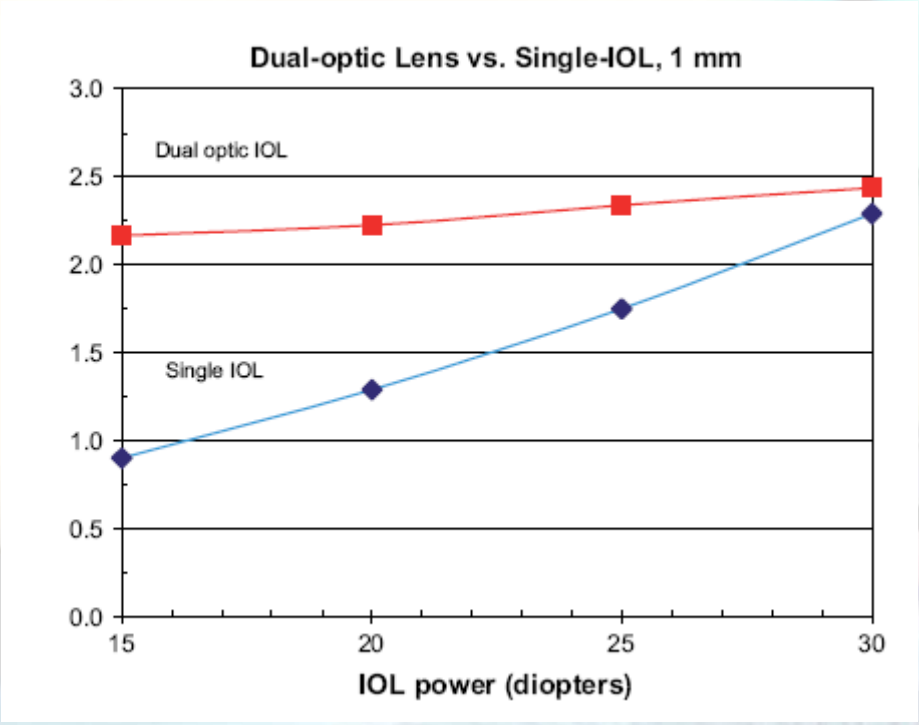

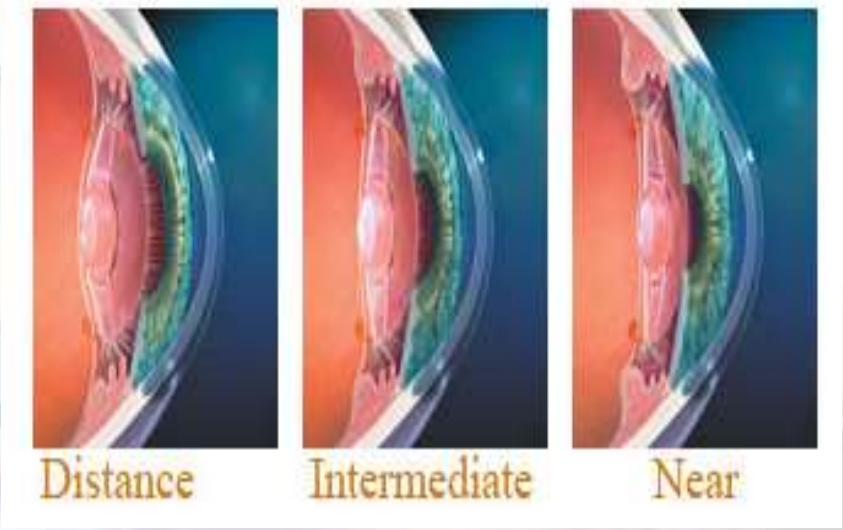

Capsular bag opacification after experimental implantation of a new accommodating intraocular lens in rabbit eyes.

Liliana Werner, MD, PhD, Suresh K. Pandey, MD, Andrea M. Izak, MD, Luis G. Vargas, MD, Rupal H. Trivedi, MD, David J. Apple, MD, Nick Mamalis, MD

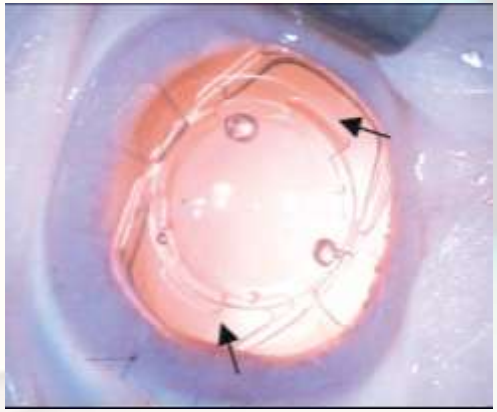

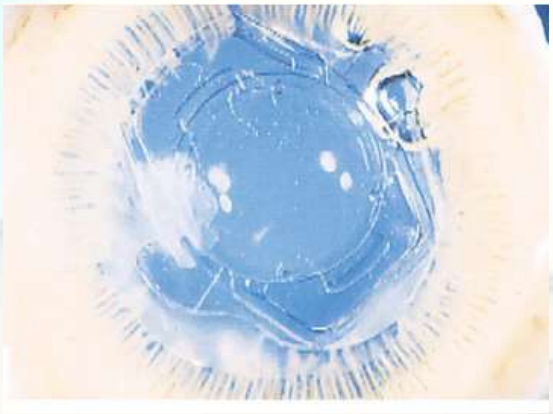

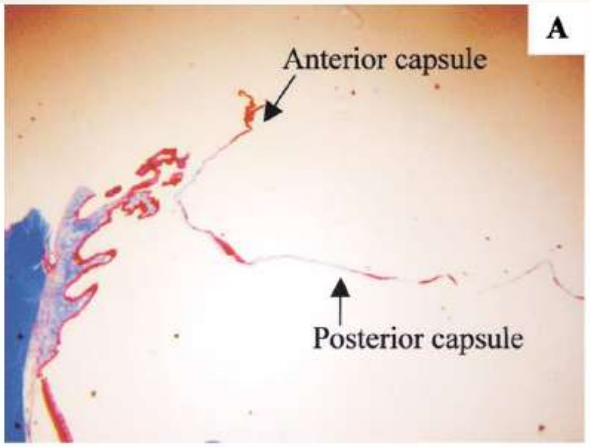

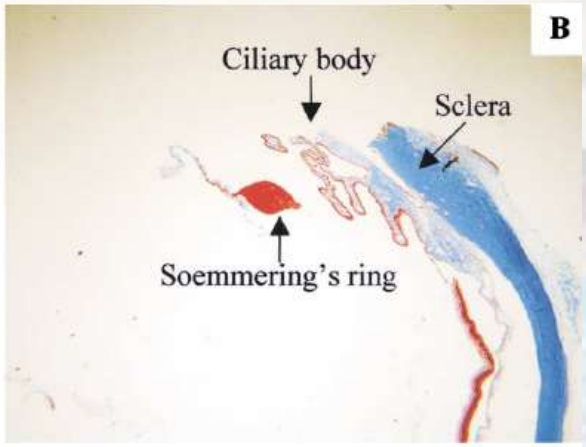



Corte Óptico de Scheimpflug OI
03/02/04 : TILTING EN 225°-45° , 900 µm

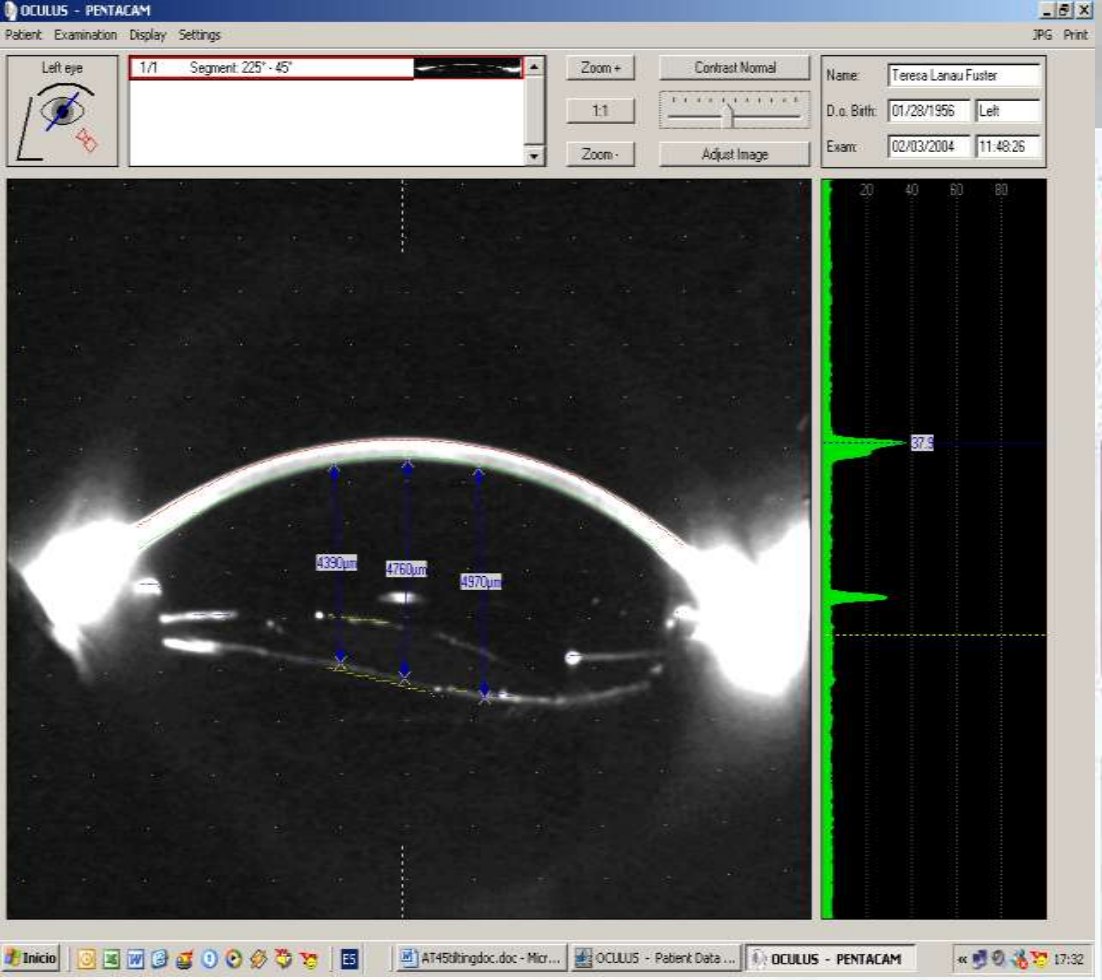



OI:0.3 (-2.00-2.11x 117°) = 0.6

(Z3,-1) 0.430µm

(Z3,1) 0.515 µm

Total Aberrations : 2.09 µm

High Order Aberratons: 0.83 µm

What kind of Multifocal IOLs ?





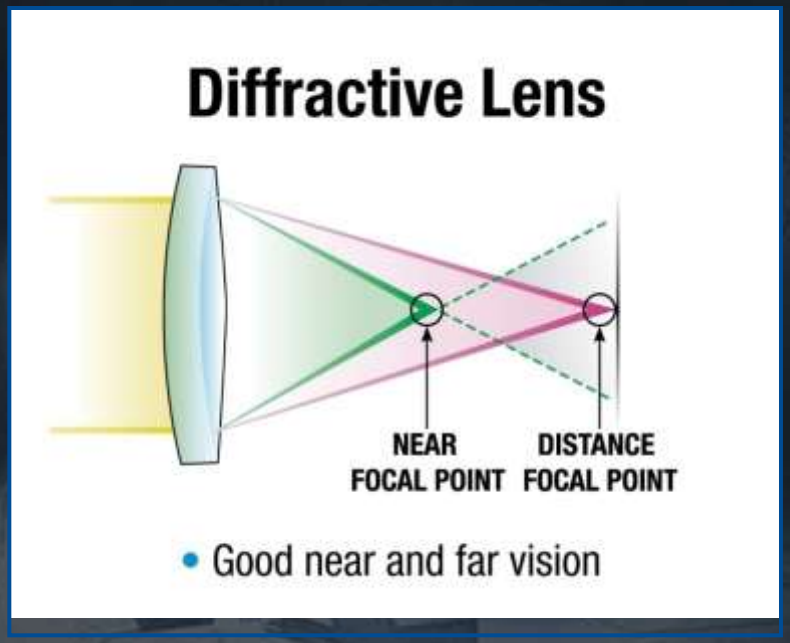

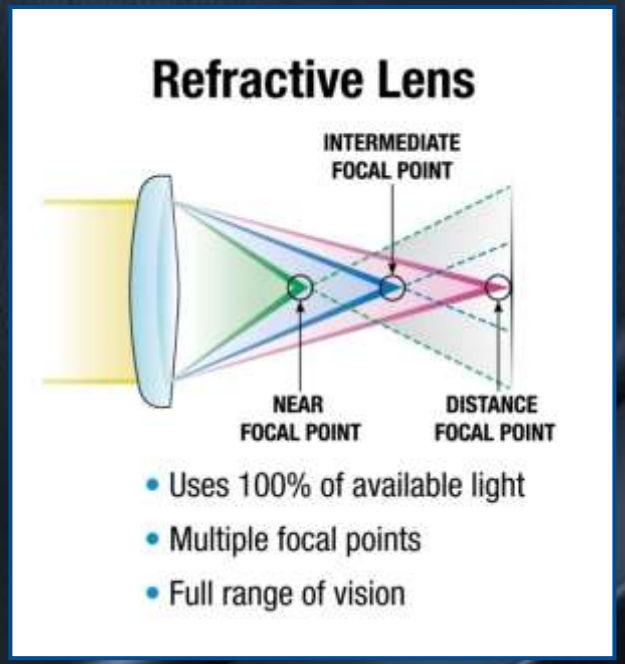

Súper-imposición de imágenes en la retina

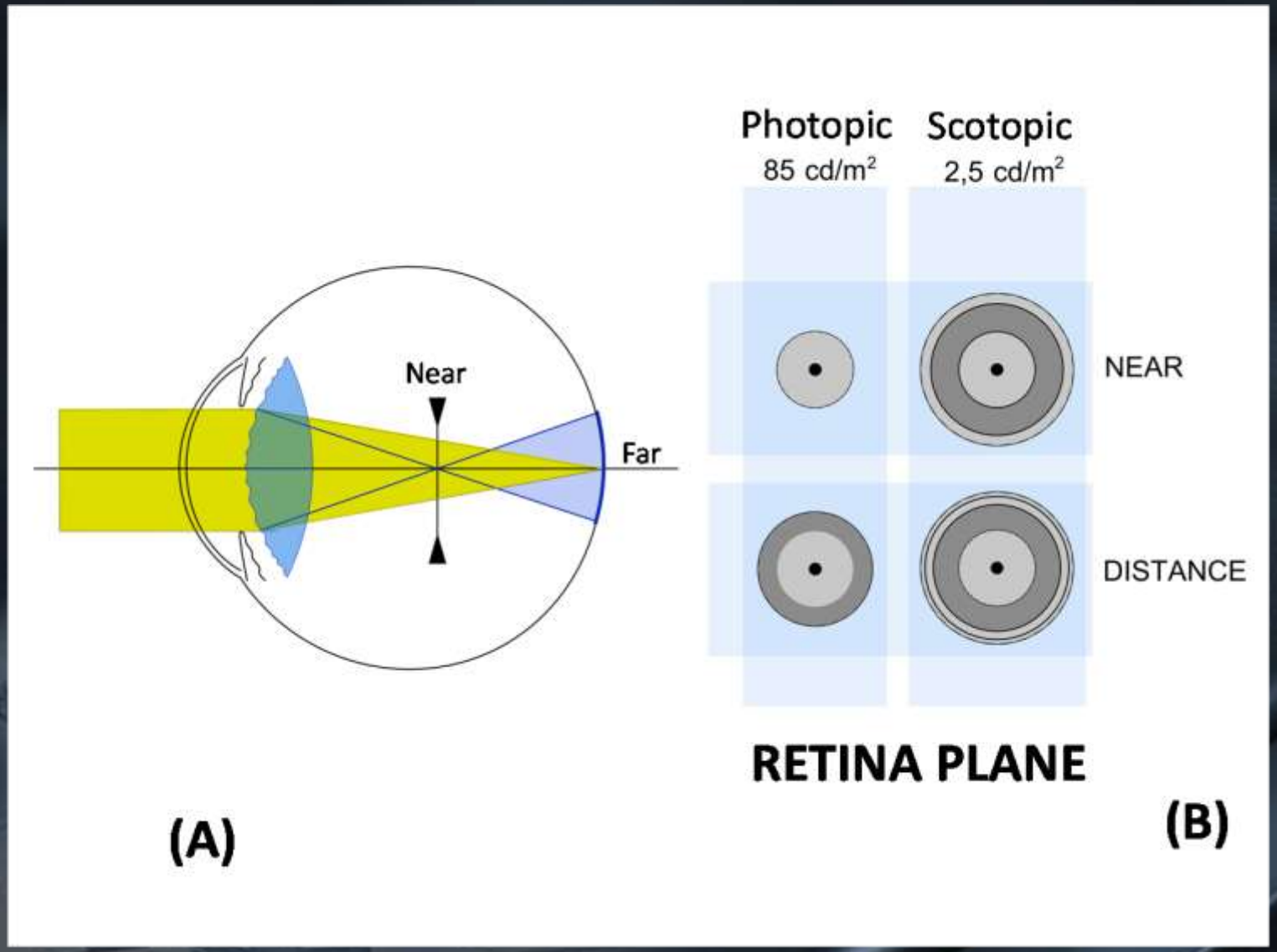

Sensación de halos y deslumbramiento

Alcon
ReSTOR



AMO
ReZoom



Tecnis
Multifocal



área oftalmológica avanzada
Dr. Vergés

CUSTOM MATCH MULTIFOCAL LENSES

- Same bilateral implant.
- Dual system by Acritec
- ReZomm and Restor or Tecnis
- Restor or Tecnis and Crysrtalens

Mix and Match

ReZoom: Dominant eye

Tecnis Mf: Non dominant eye

“Mix and Match”

ReZoom : Dominant eye

Tecnis Mf : Non dominant eye

Global Satisfaction

- 1: Poor .
- 2: Aceptable.
- 3: Good.
- 4: Very Good.
- 5: Excelente.

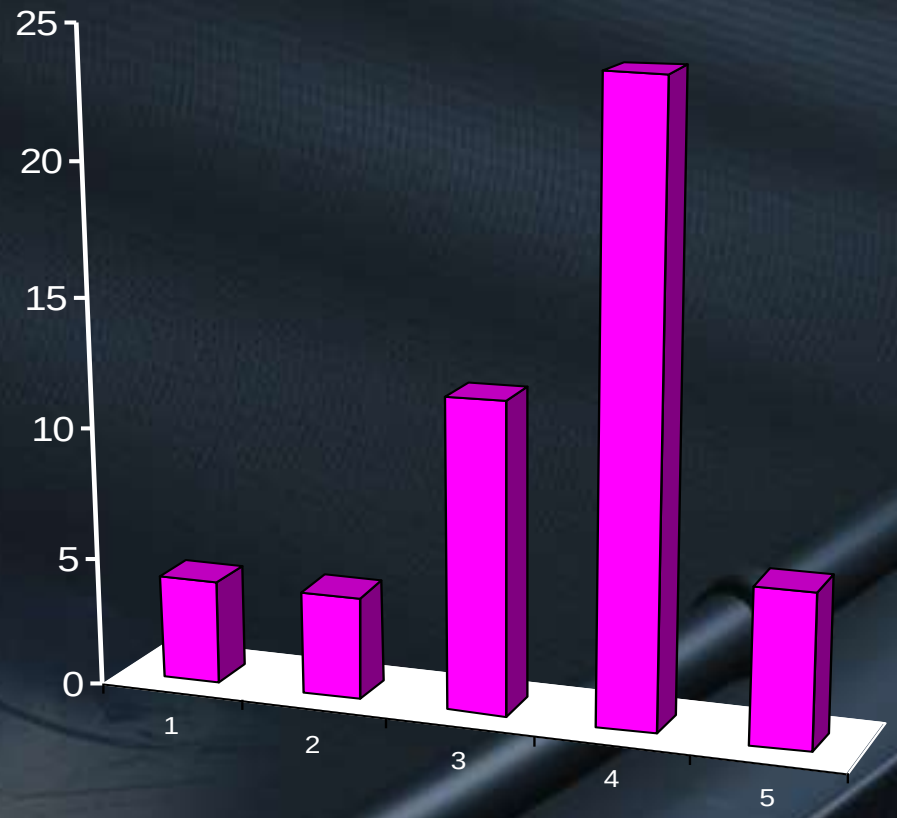

Near Spectacle Dependency

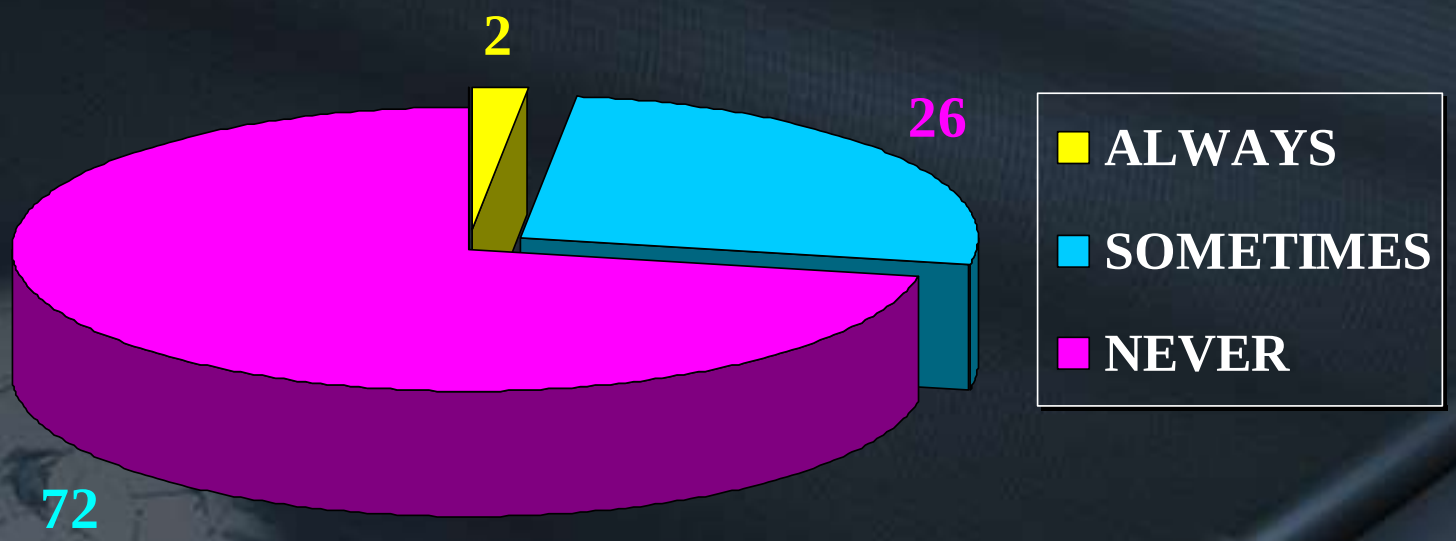

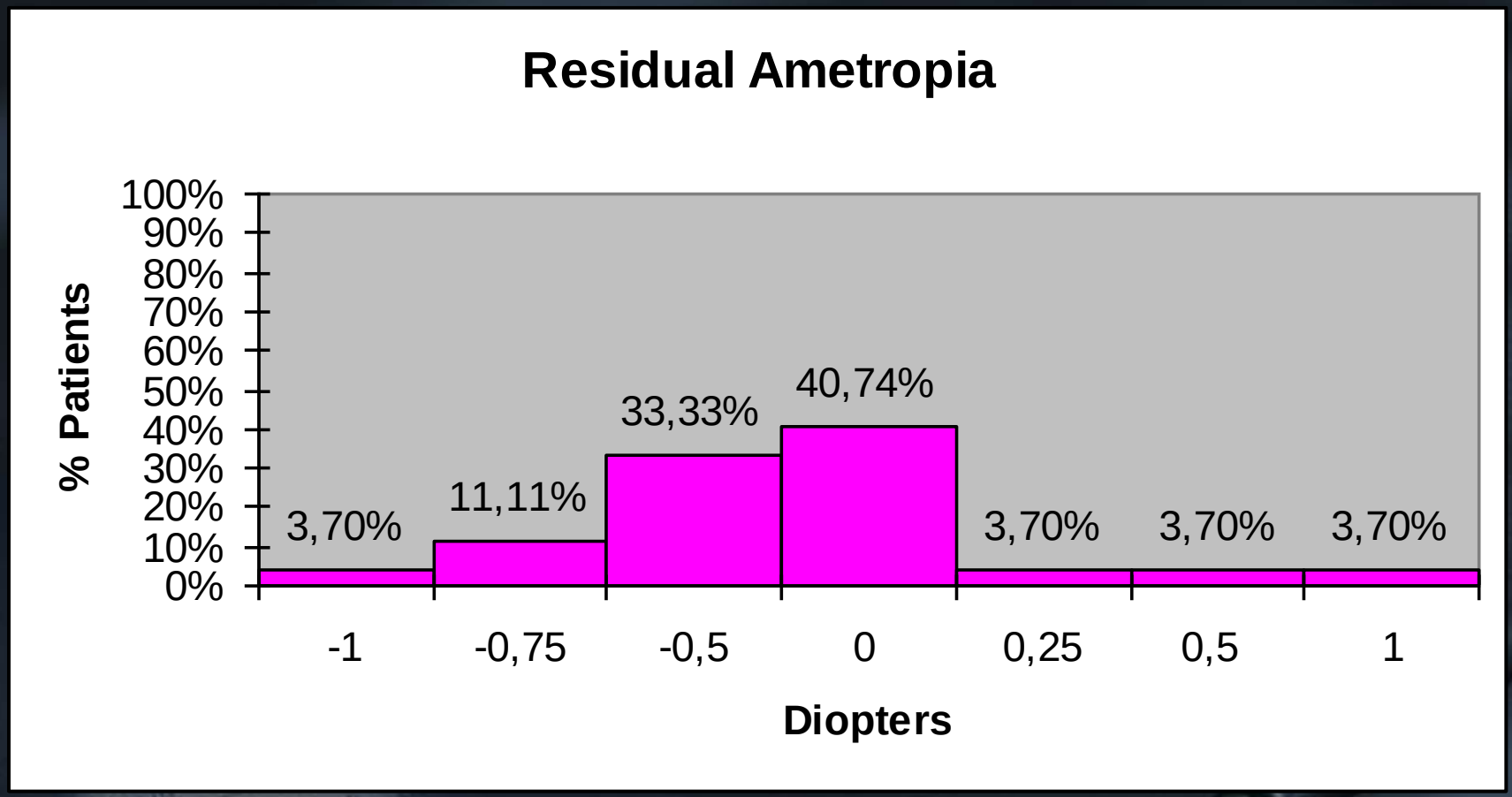
Residual Ametropia
% Patients
100%
90%
80%
70%
60%
50%
40%
30%
20%
10%
0%
3,70%
11,11%
33,33%
40,74%
3,70%
3,70%
3,70%
-1
-0,75
-0,5
0
0,25
0,5
1
Diopters

área oftalmológica avanzada
Dr. Vergés

MONOVISIÓN CON LIOs MONOFOCALES

Mejora de la calidad óptica

MINIFLEX

- Flexacryl® New acyclic copolymer with hydrophobic and hydrophilic monomers.
- The new material allows to implant the lens through incisions sub 2 mm.
- Haptics with variable rigidity to better auto-center.
- Double square edges to better control of the PCO.
- Optics designed with Wavefront guided software and neutral asphericity.

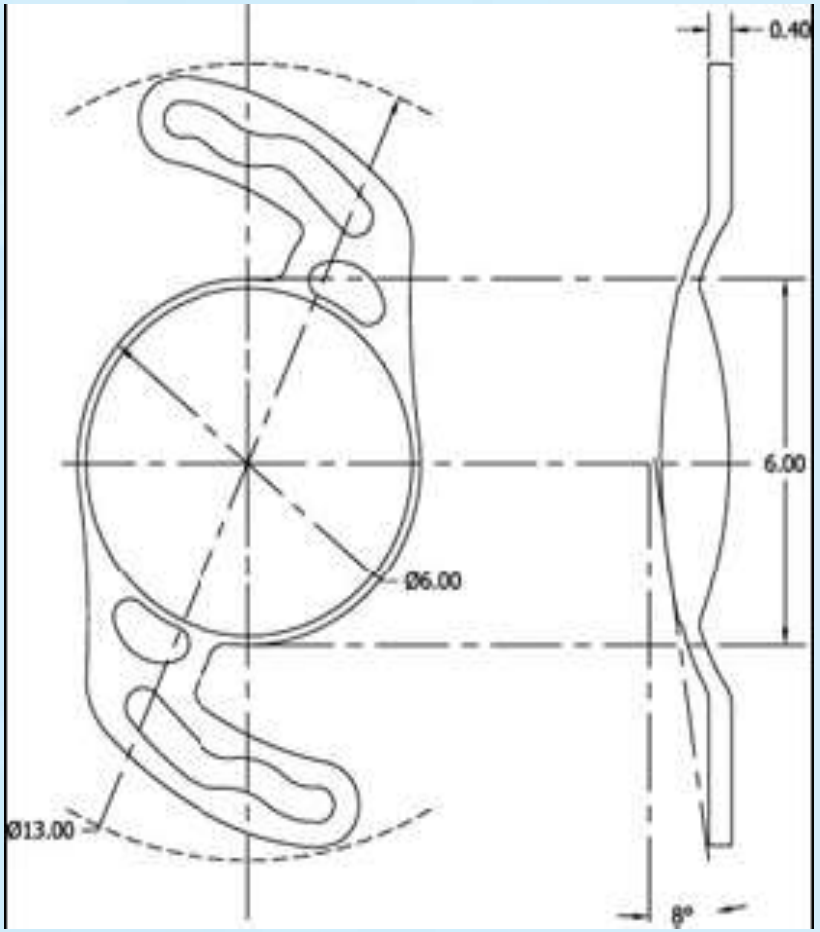

MEDIPHACOS
OPHTHALMIC PROFESSIONALS

MINIFLEX

- Flexacryl® New acyclic copolymer with hydrophobic and hydrophilic monomers.
- The new material allows to implant the lens through incisions sub 2 mm.
- Haptics with variable rigidity to better auto-center.
- Double square edges to better control of the PCO.
- Optics designed with Wavefront guided software and neutral asphericity.

	Corneal Aberrations	Lens Aberrations
Young eye	+ 0.30 µ	- 0.20 µ
Acri Smart	+ 030 µ	- 0.26 µ
Acri Sof IQ	+ 0.30 µ	- 0.20 µ
Tecnis Z 9000	+ 0.30 µ	- 0.27 µ
Akreos Adapt	+ 0.30 µ	0 µ
Miniflex	+ 0.30 µ	0 µ

MINIFLEX

Lab. analysis, PSF



2 mm



4 mm



6 mm



MINIFLEX

Dect. 0.5 mm Tilting 8º		Miniflex Mediphacos)	AR 40 AMO	Akreos Adapt B & L
M.T.F. mm	4	**15.8 %**	**15.2 %**	13.1 %
	6 mm	23.5 %	**25.7 %**	**27.4 %**
P.S.F. mm	4	12.8 %	**14.3 %**	**15.9 %**
	6 mm	19.4 %	**20.6 %**	**24.6 %**
H.O. mm	4	**12.5 %**	**11.8 %**	**14.6 %**
	6	18.0 %	**18.2 %**	**20.2 %**

P < 0.004

área oftalmológica avanzada
Dr. Vergés

TERAPIA VISUAL

Mejorar la sensibilidad al contraste y la profundidad de campo





área oftalmológica avanzada
Dr. Vergés

QUÉ ESTOY HACIENDO HOY PARA TRATAR LA PRESBICIA



Analizar cada caso y decidir con el paciente

- Edades entre 40 y 55 años con “cristalino sano”:
  - Terapia Visual
  - Láser con ablación hiperprolata
  - Monovisión con Lentillas

- Edad > 55 años:
  - Monovisión con LIO monofocal asférica neutra y Terapia Visual

área oftalmológica avanzada
Dr. Vergés

Gracias por vuestra atención

